



PRACHAND NEET



ONE SHOT



Zoology

Human Reproduction

→ 3-4 Ques

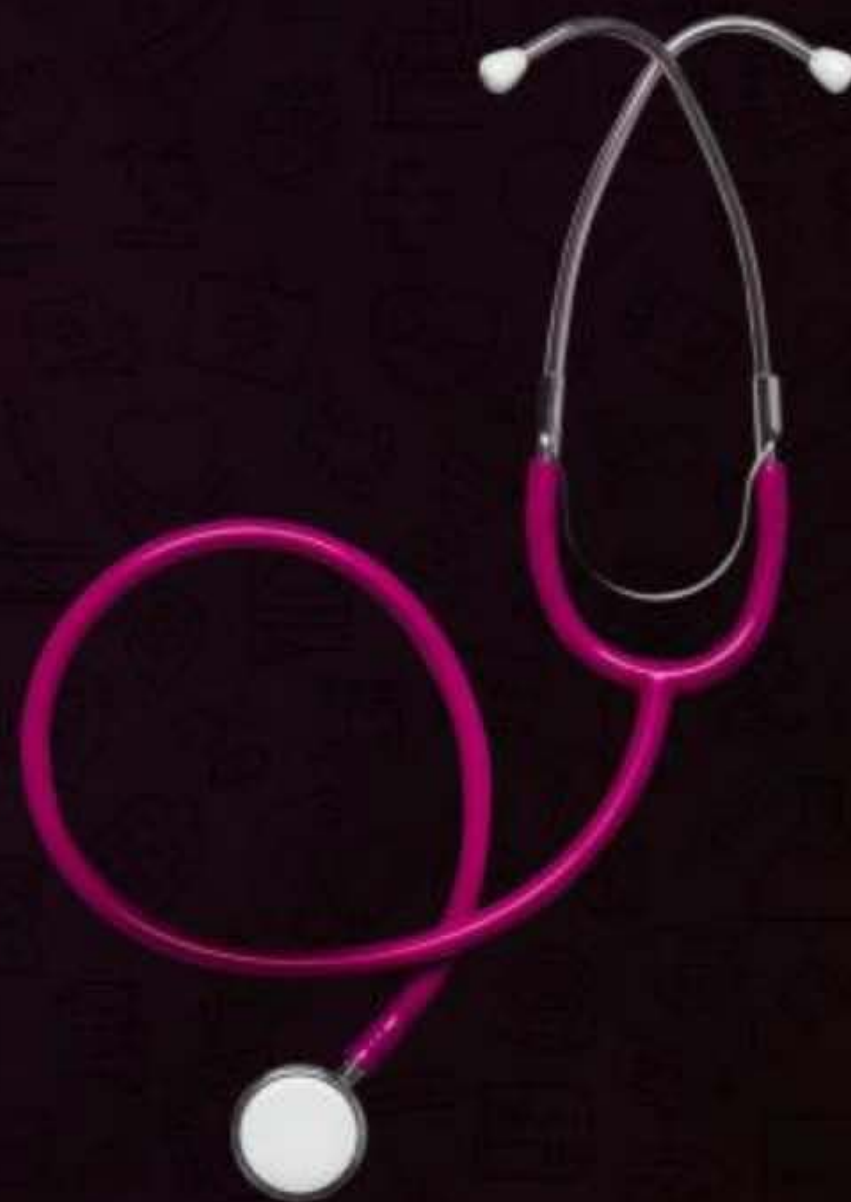

Dr. Akanksha Agarwal Ma'am



Topics *to be covered*

- 1 Complete chapter



PRACHAND SERIES

TELEGRAM CHANNEL



@PW_YAKEENDROPPER

NEET-2025

100%

Happy
& Peaceful

- * Basics - - - - > NEET
- * NCERT ^{Theory} Tips (Underst → Learn)
- * MCQs (All types)
- * PYQs
- * NCERT : Assertion-Reason
- * Short Notes
complete NCERT
- * Immunity Boosted
- * Boards ✓



Immunity Booster = Short Notes

* GESTATION

- Average duration of Human Pregnancy
- 9 months
- Dogs: 52-65 days
- Cats
- Elephant: 18-22 months (longest)

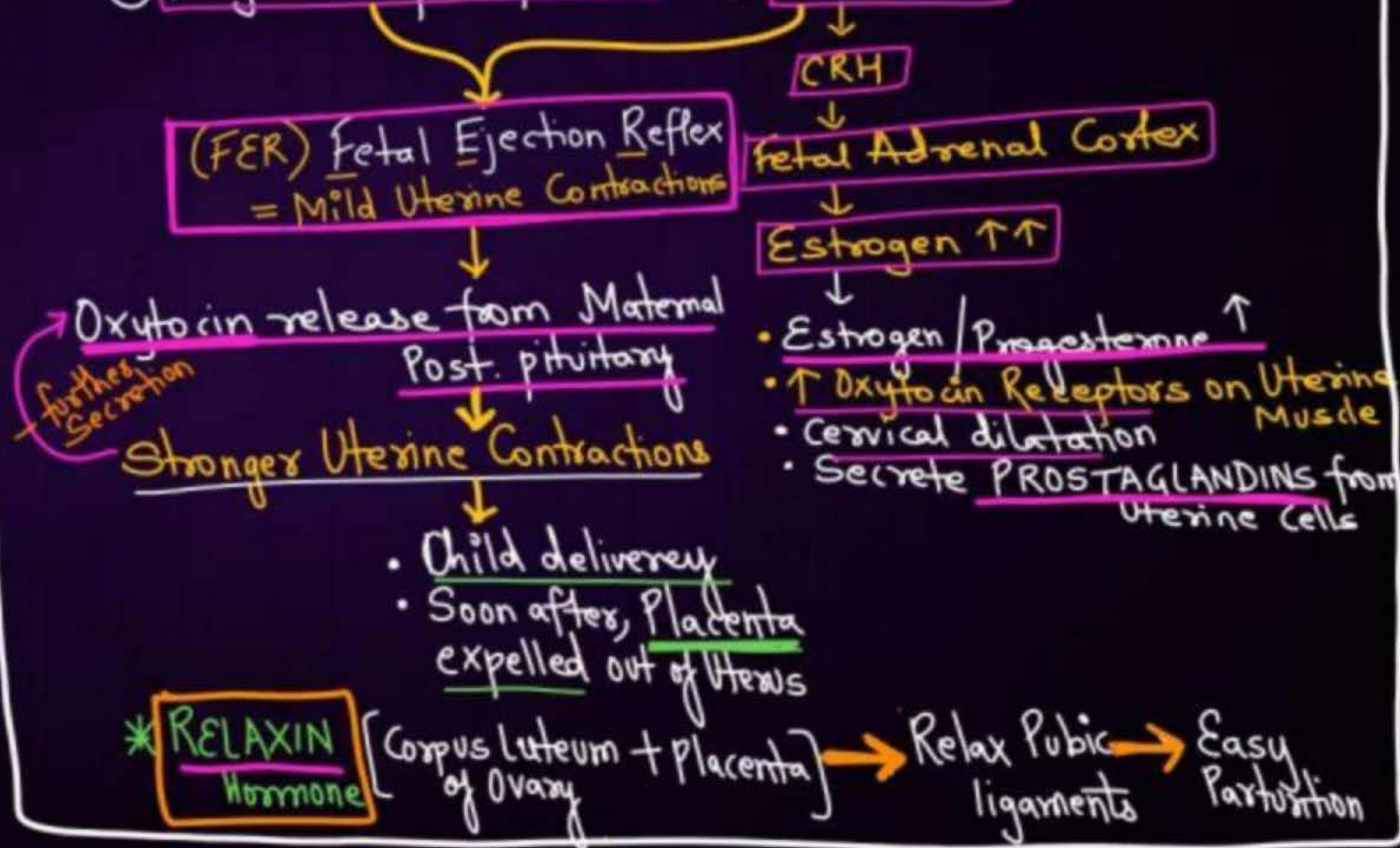
LACTATION

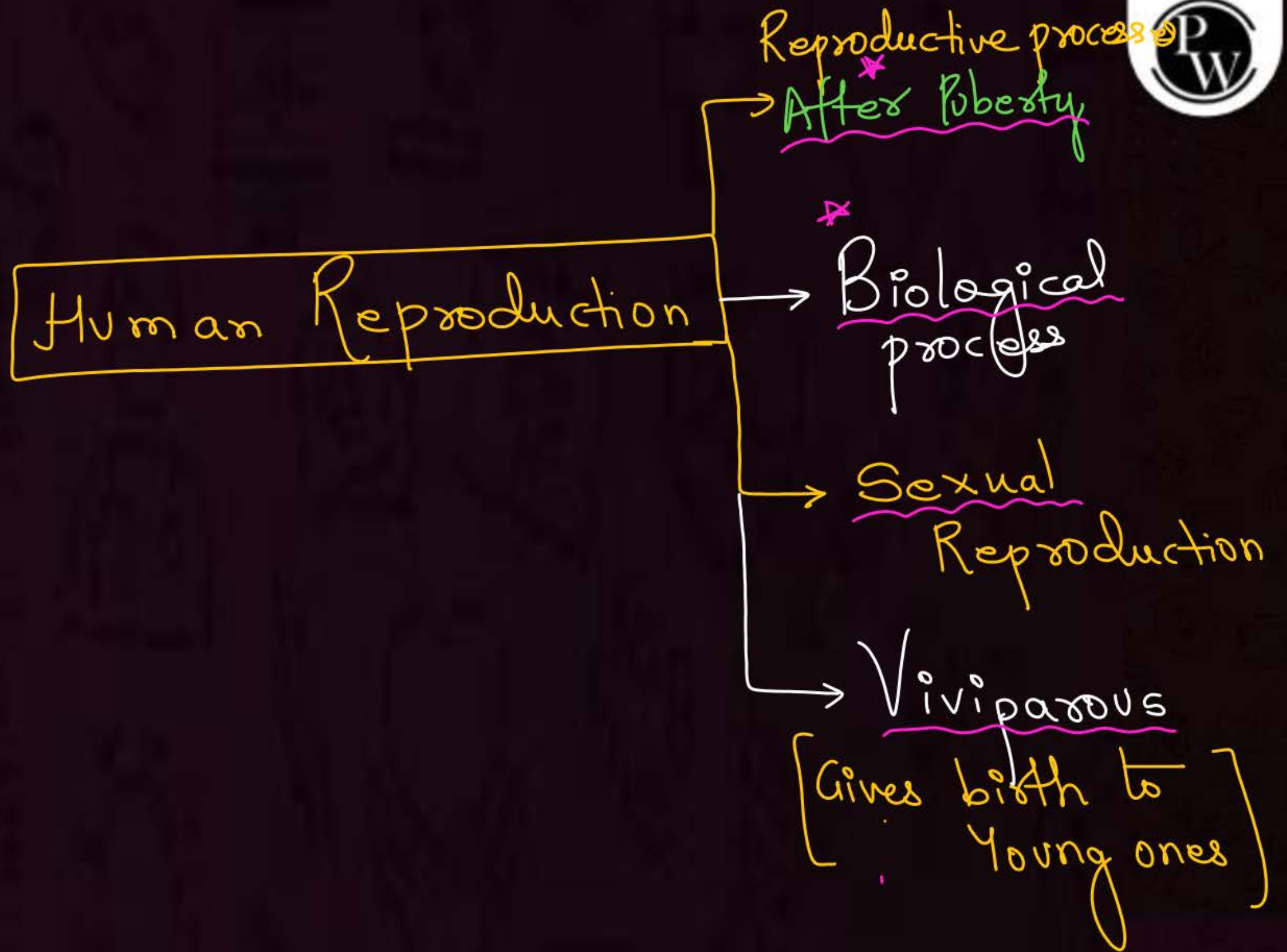
- Milk production, start towards End of Pregnancy; feed newborn
- COLOSTRUM = Initial few days milk
→ Several Antibodies
- MILK SECRETION $\xrightarrow{\text{IgA}}$ Prolactin, hPL
- MILK EJECTION/LET-DOWN \rightarrow OXYTOCIN



Parturition = Delivery of baby (foetus) or Expulsion of baby out of Uterus, through birth Canal
 { Complex Neuro-endocrine mechanism
 Signals for Parturition Originate from Both:

① Fully developed foetus ② Placenta





SEXUAL REPRODUCTION—3 Events



I PRE-FERTILISATION:

1. Gametogenesis
2. Gamete Transfer

II FERTILISATION SYNGAMY

III Post-FERTILISATION





I PRE-FERTILIS

GAMETOGENESIS

Formation of ♂ and ♀ Gametes

In ♂, Sperm formation continues even in old age

In ♀, ovum formation stops around 50 yrs of age

INSEMINATION

Transfer of ♂ gametes (Semen) into ♀ Reproductive Tract (Vagina)

II

FERTILISATION | SYNGAMY

Fusion of both gametes to form a Zygote

ZYGOTE Formation



III
POST-
FERTIL.

↓
Formation & development of Blastocyst

↓
IMPLANTATION

Attachment of Blastocyst
into Uterine Wall

↓
GESTATION

Embryonic
development

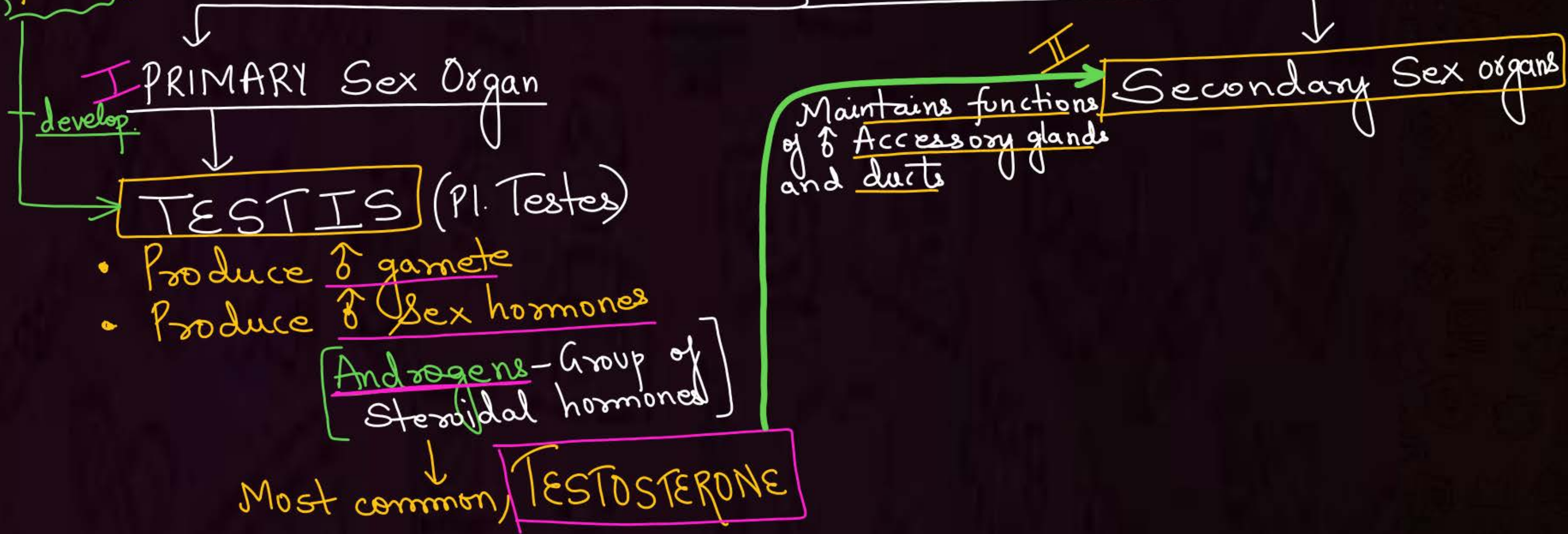
[Human = 9 months
7 days
EDD = LMP + 9 months
7 days]

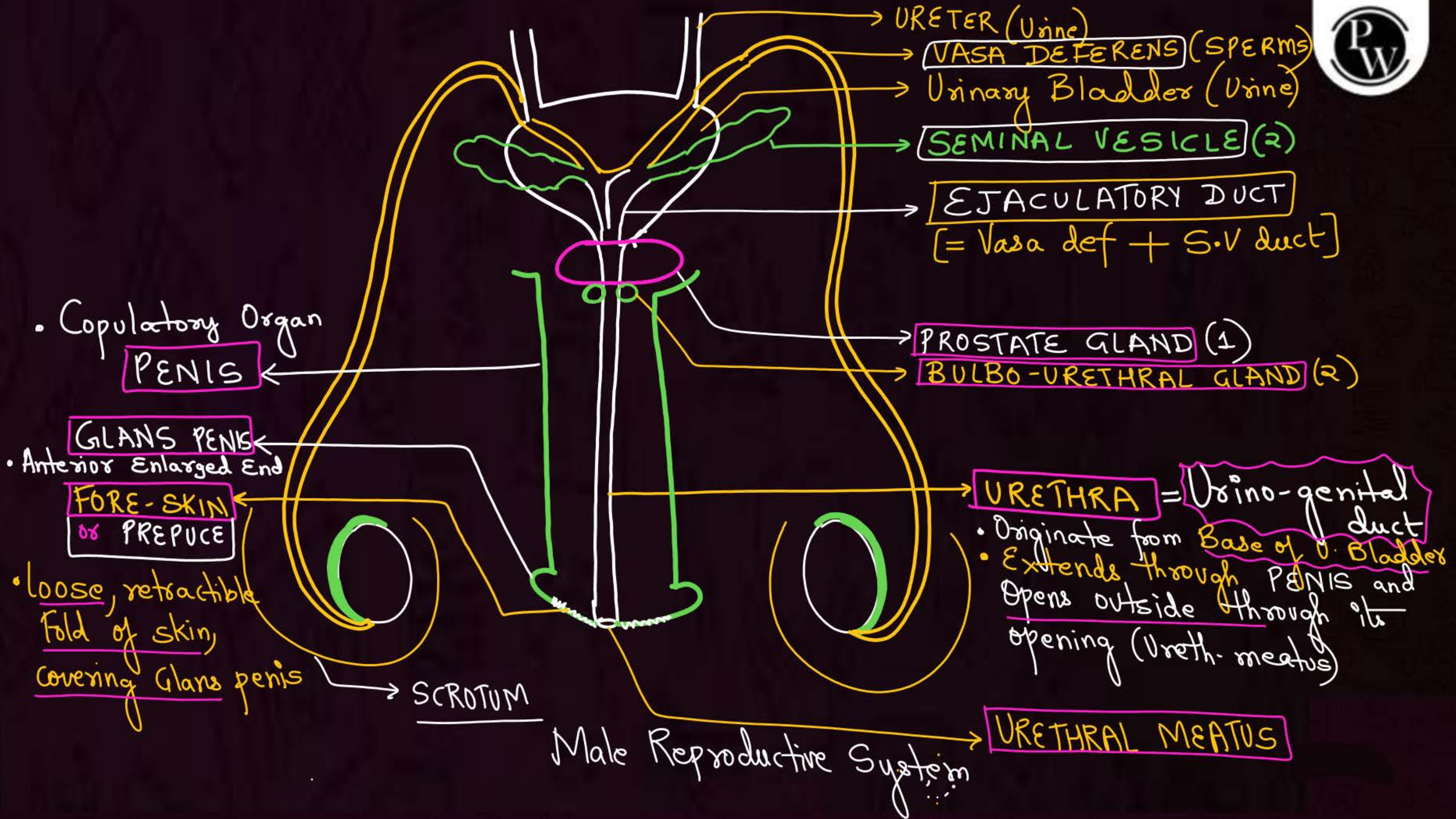
↓
PARTURITION | Child birth | delivery

↓
LACTATION | Breast feeding

MALE REPRODUCTIVE SYSTEM

FSH (Ant. Pit.)





* TESTIS:-

✓ 1 Pair

✓ Oval shape

✓ Width 2-3 cm

✓ Length 4-5 cm

✓ Outside Abdominal Cavity,
in a pouch - SCROTUM

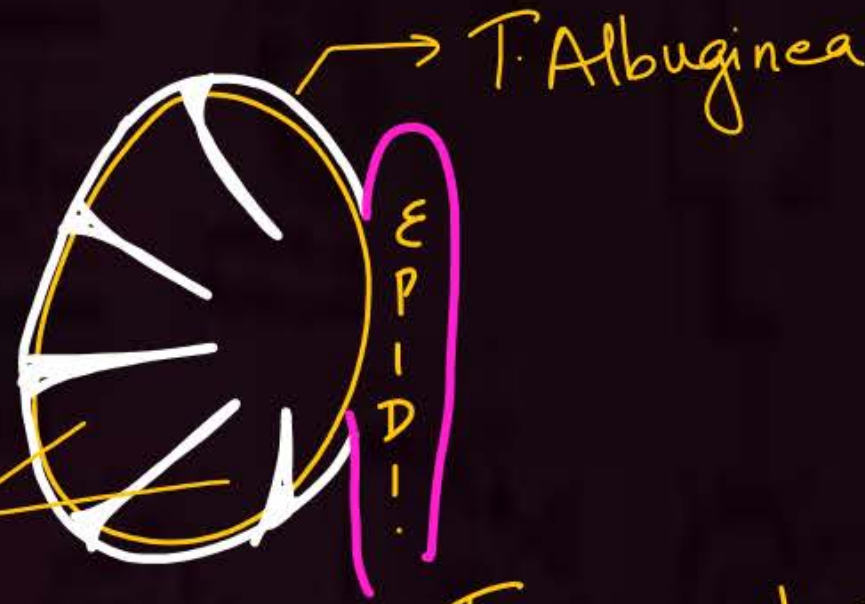
✓ Formed inside Abdomen, But
descends to Scrotum through
Inguinal Canal (during 7th month preg)

✓ Covered by a dense covering, TUNICA ALBUGINEA

✓ 250 testicular lobules in Each testis
(compartments due to invagination of T. albuginea)



Testicular lobules



To maintain
temp. 2-2.5°C
lower than body
temp.

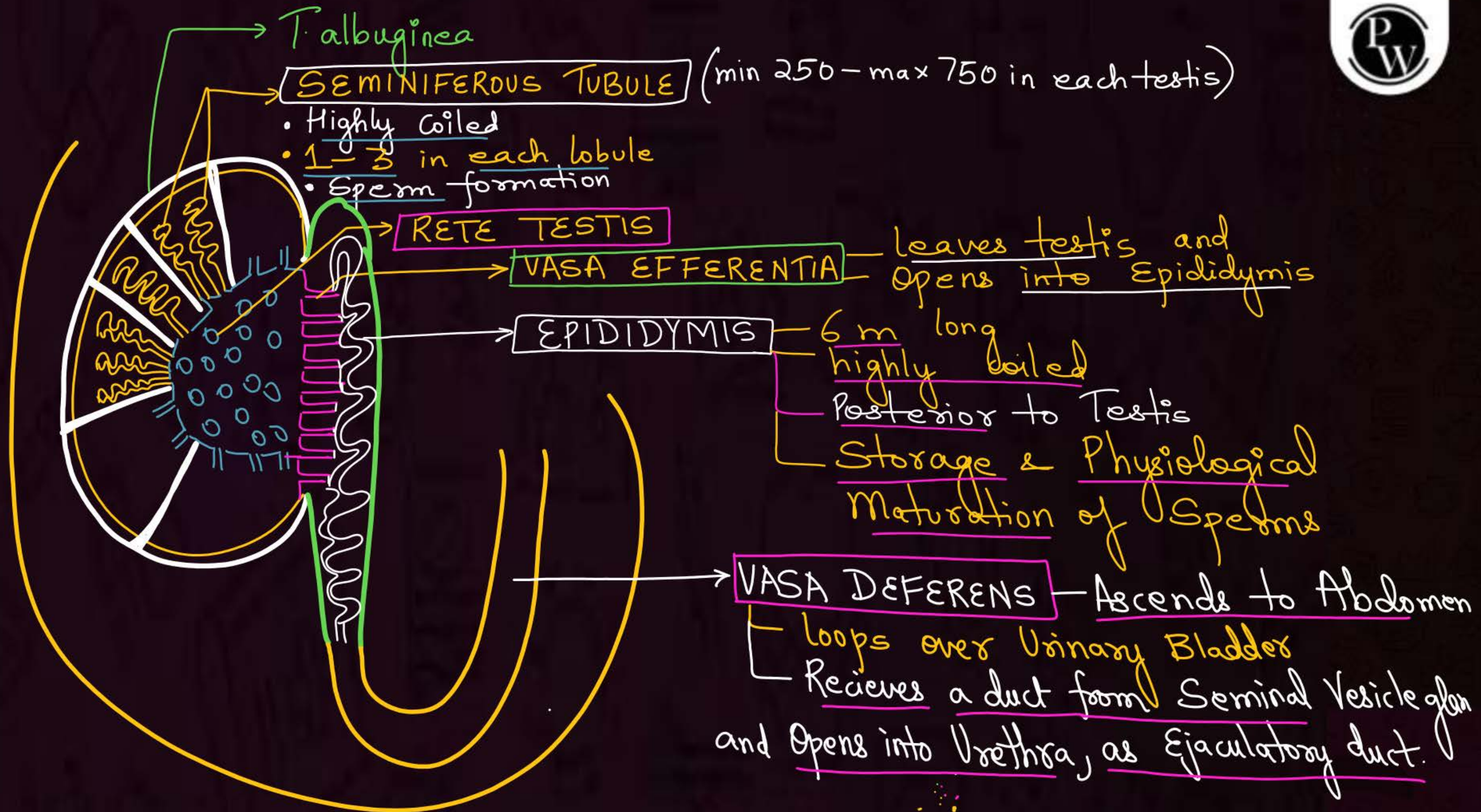
AR

Necessary
for
Spermato-
genesis



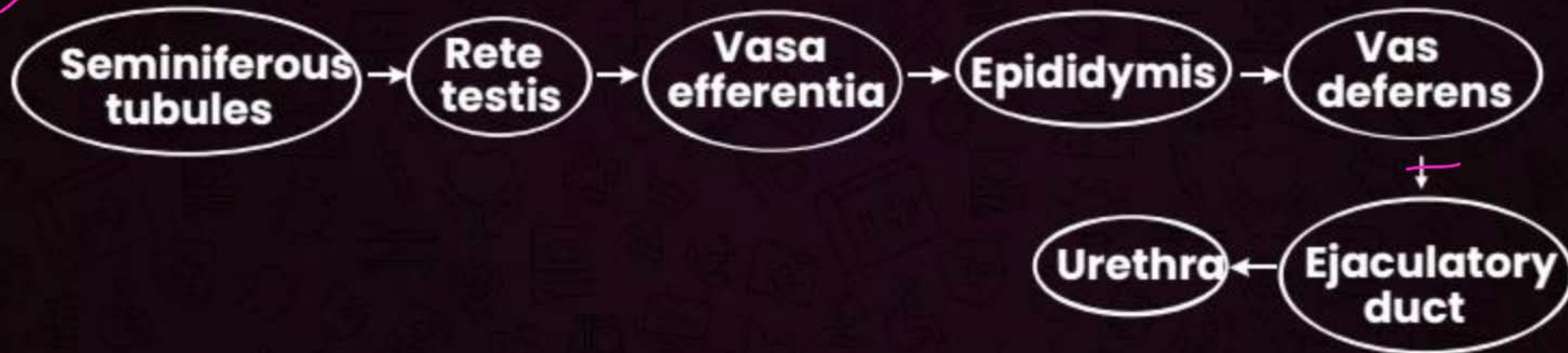SCROTUM

Out of
NCERT



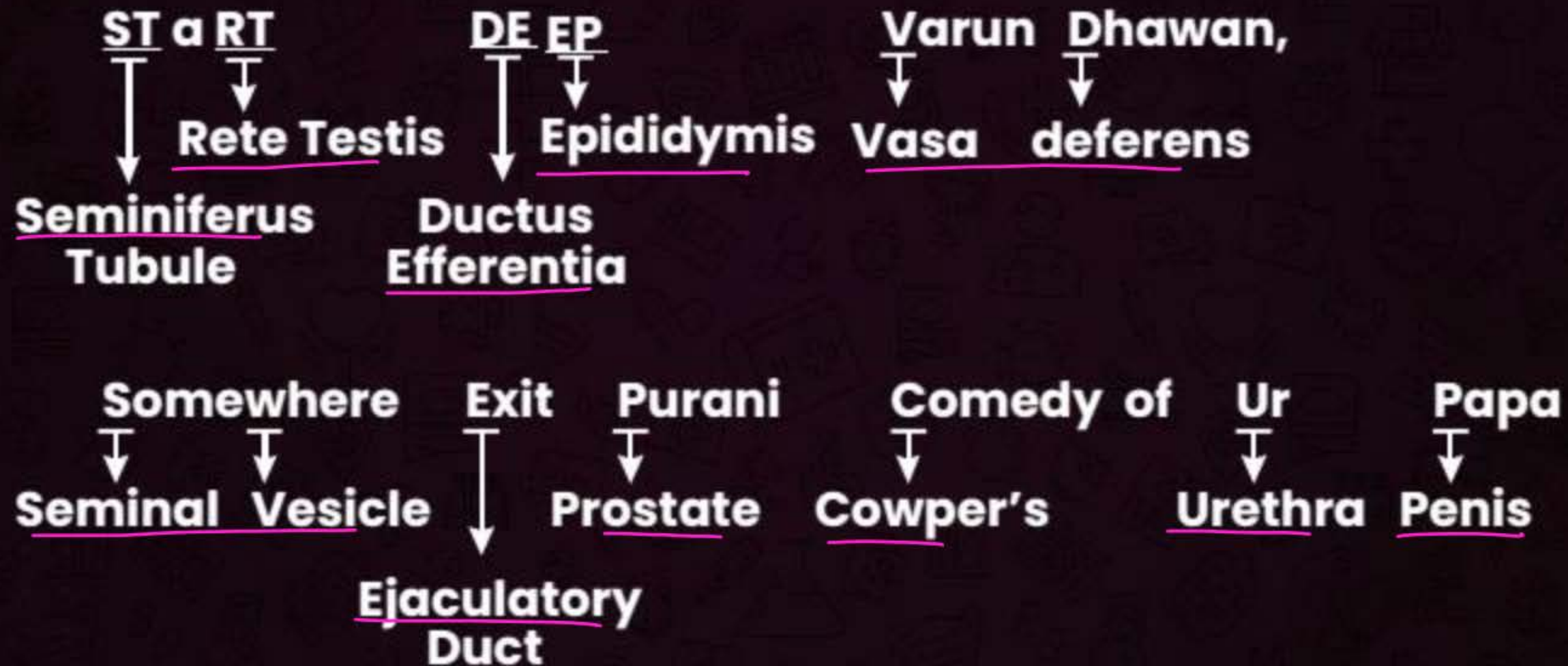
PYQ

Path of Sperm through the Male Body




———— **FOR NOTES & DPP CHECK DESCRIPTION** ————

Trick for pathway of Sperm/semen :-



———— **FOR NOTES & DPP CHECK DESCRIPTION** ————

 * SEMEN = SPERMS + S.V + Prostate + Bulbo-urethral secretions
= Seminal Plasma

* 1 Ejaculate = 2-3 ml Semen

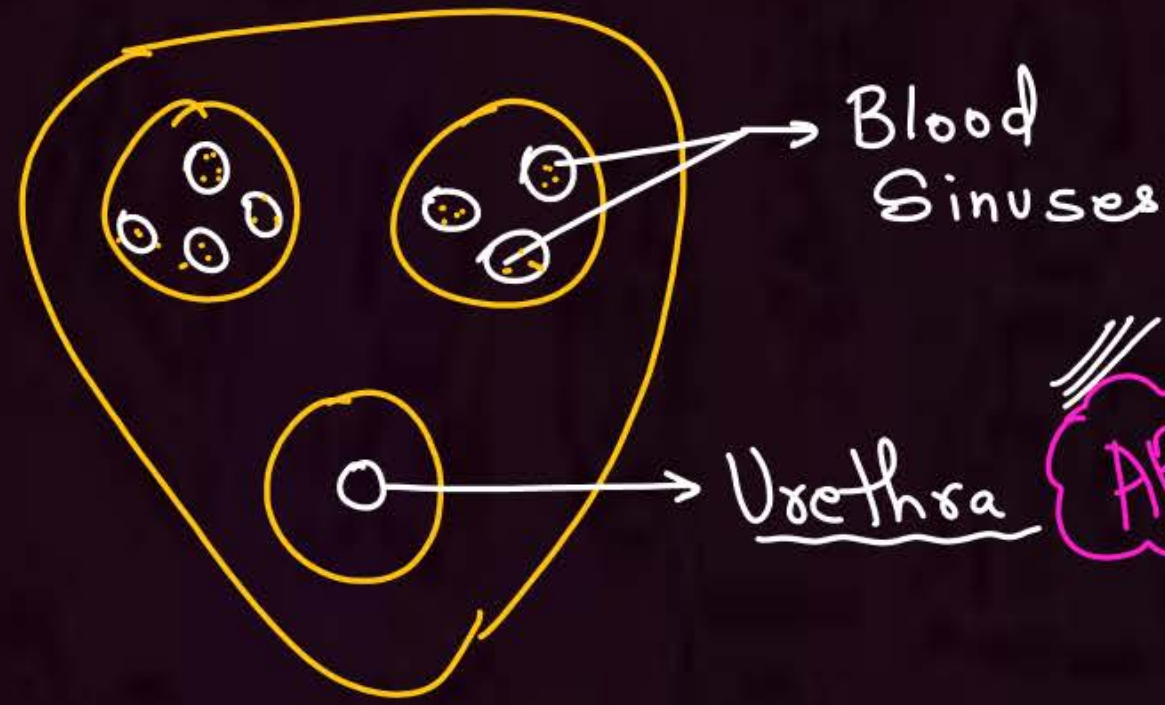
1 ml Semen = 100 million Sperms

1 Ejaculate = 200-300 million Sperms

* 1. S.V → 2 (1 pair), FRUCTOSE, Prostaglandins } other Enzymes
2. Prostate → 1 (single), Calcium
3. Bulbo-urethral → 2 (1 pair), lubricate penis

* NOTE: Secretions of S.V, Prostate, Epididymis, Vasa deferens are essential for Maturation and Motility of Sperms

* **PENIS** — Special Erectile tissue



* Parasympathetic ANS

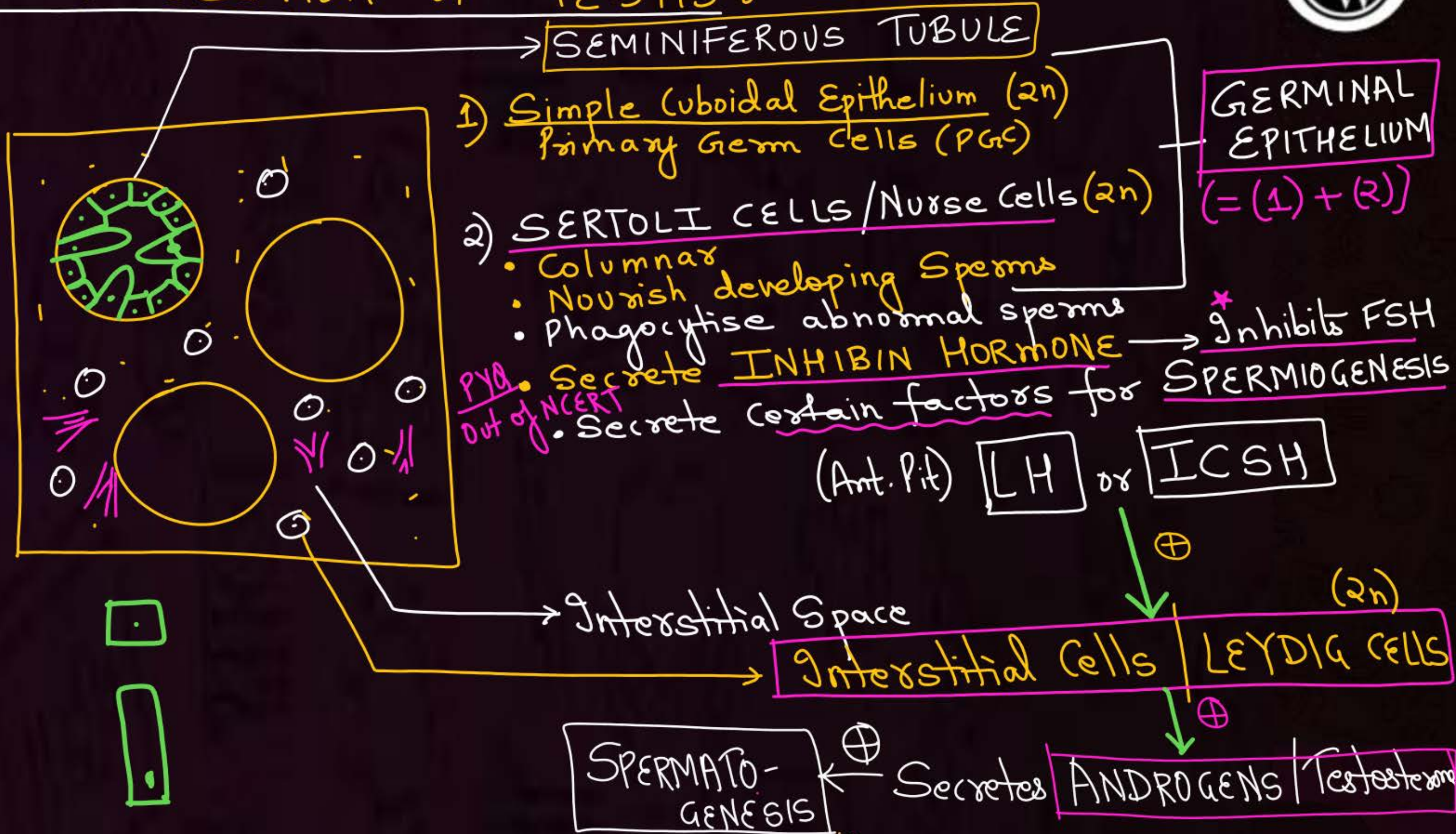
* **ERECTION OF PENIS** [Hardening]

* **to Facilitate Insemination**

* Sympathetic ANS

Ejaculation (Forceful Release of Semen)

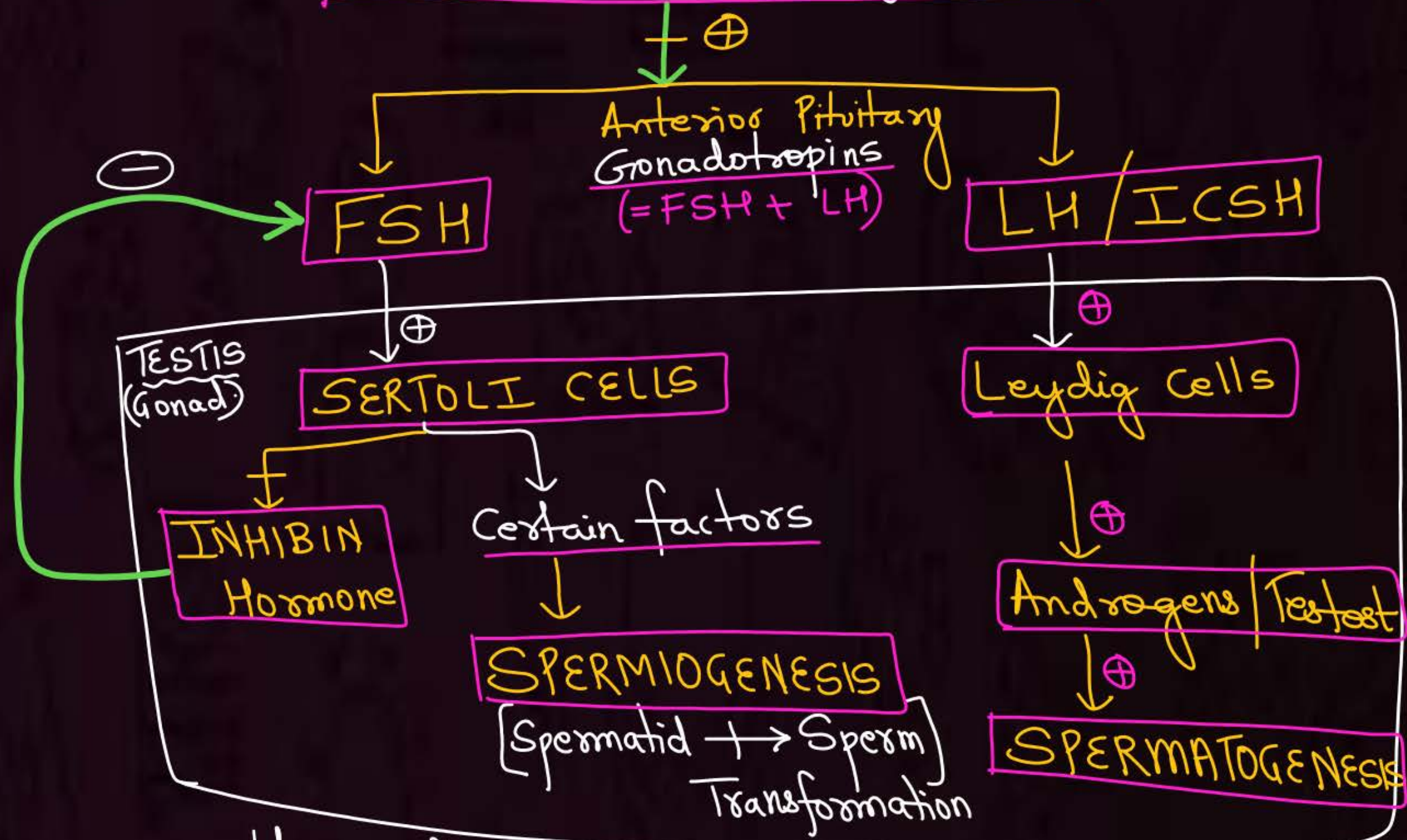
* CUT-SECTION OF TESTIS :-



* Interstitial Space contains:-

- 1) Interstitial Cells / Leydig Cells
- 2) Small Blood vessels
- 3) Immunologically Competent Cells

At Puberty (Hypothalamus) Gonadotropin Releasing Hormone (GnRH)

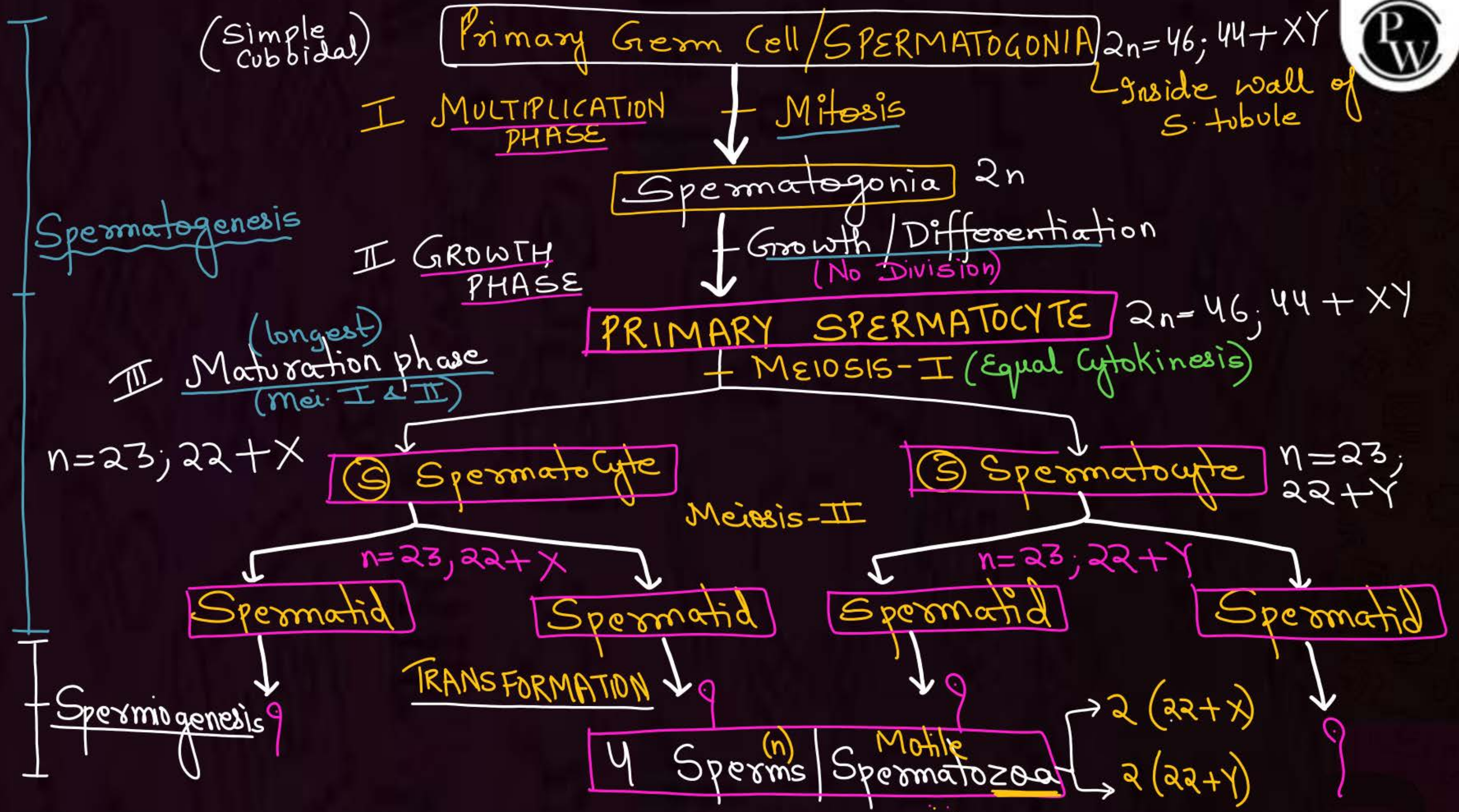


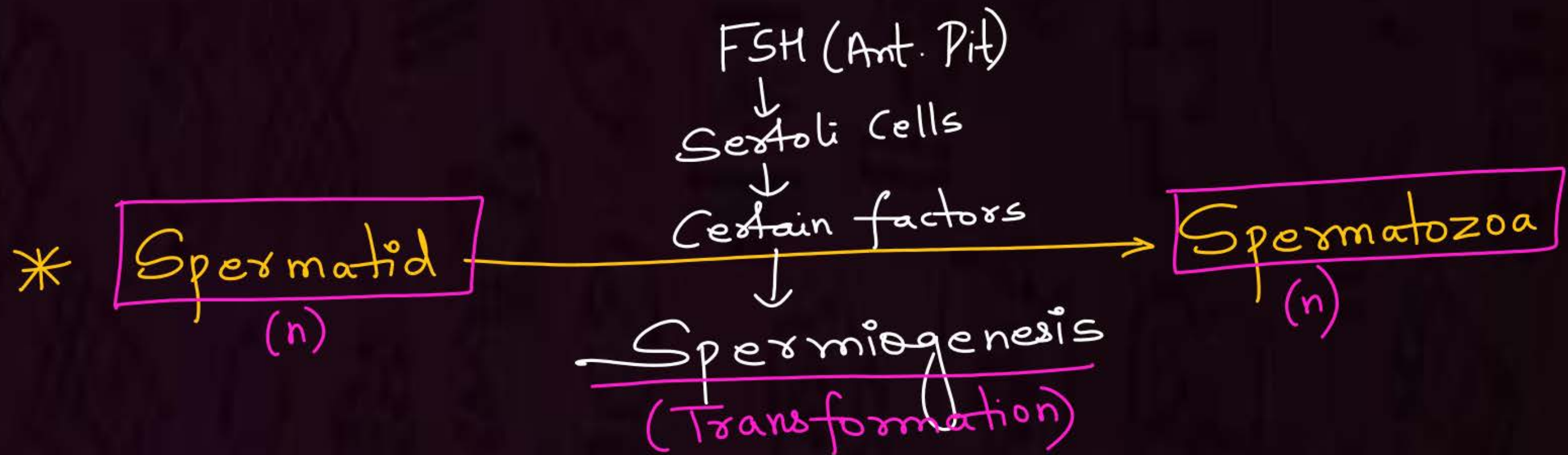
Hormonal Regulation in Male

SPERMATOGENESIS

- ✓ Starts at PUBERTY
- ✓ Inside Seminiferous tubules







* SPERMIAATION : Sperms, embedded in Sertoli cells, detaches its ^{head} from Sertoli cells, and is released into lumen of Seminiferous tubule (NTA)

PYQ
2022
NEET

[NCERT :- Released from S. tubule]



Master
NCERT

As you are aware, humans are sexually reproducing and viviparous. The reproductive events in humans include formation of gametes (gametogenesis), i.e., sperms in males and ovum in females, transfer of sperms into the female genital tract (insemination) and fusion of male and female gametes (fertilisation) leading to formation of zygote. This is followed by formation and development of blastocyst and its attachment to the uterine wall (implantation), embryonic development (gestation) and delivery of the baby (parturition). You have learnt that these reproductive events occur after puberty. There are remarkable differences between the reproductive events in the male

———— **FOR NOTES & DPP CHECK DESCRIPTION** ————

and in the female, for example, sperm formation continues even in old men, but formation of ovum ceases in women around the age of fifty years. Let us examine the male and female reproductive systems in human.

2.1 THE MALE REPRODUCTIVE SYSTEM

The male reproductive system is located in the pelvis region (Figure 2.1a). It includes a pair of **testes** alongwith **accessory ducts, glands** and the **external genitalia**.

The testes are situated outside the abdominal cavity within a pouch called **scrotum**. The scrotum helps in maintaining the **low temperature** of the testes ($2-2.5^{\circ}\text{C}$ lower than the normal internal body temperature) necessary for spermatogenesis. In adults, each testis is oval in shape, with a length of about 4 to 5 cm and a width of about 2 to 3 cm. The testis is covered by a dense covering. Each testis has about 250 compartments called **testicular lobules** (Figure 2.1b).

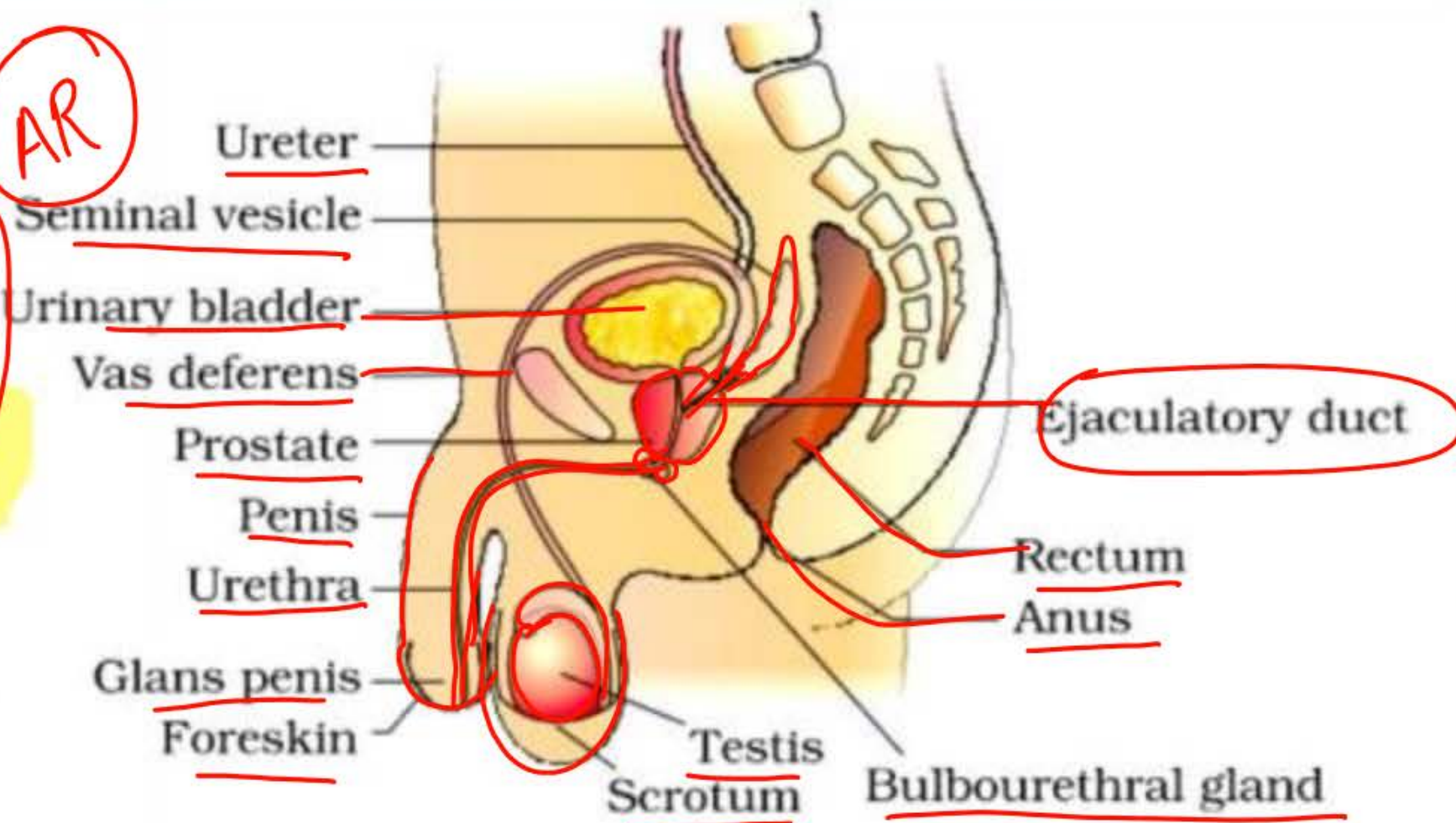


Figure 2.1(a) Diagrammatic sectional view of male pelvis showing reproductive system

Each lobule contains one to three highly coiled **seminiferous tubules** in which sperms are produced. Each seminiferous tubule is lined on its inside by two types of cells called **male germ cells** (*spermatogonia*) and **Sertoli cells** (Figure 2.2). The male germ cells undergo meiotic divisions finally leading to sperm formation, while Sertoli cells provide nutrition to the germ cells. The regions outside the seminiferous tubules called interstitial spaces, contain small blood vessels and **interstitial cells** or **Leydig cells** (Figure 2.2). Leydig cells synthesise and secrete testicular hormones called androgens. Other immunologically competent cells are also present.

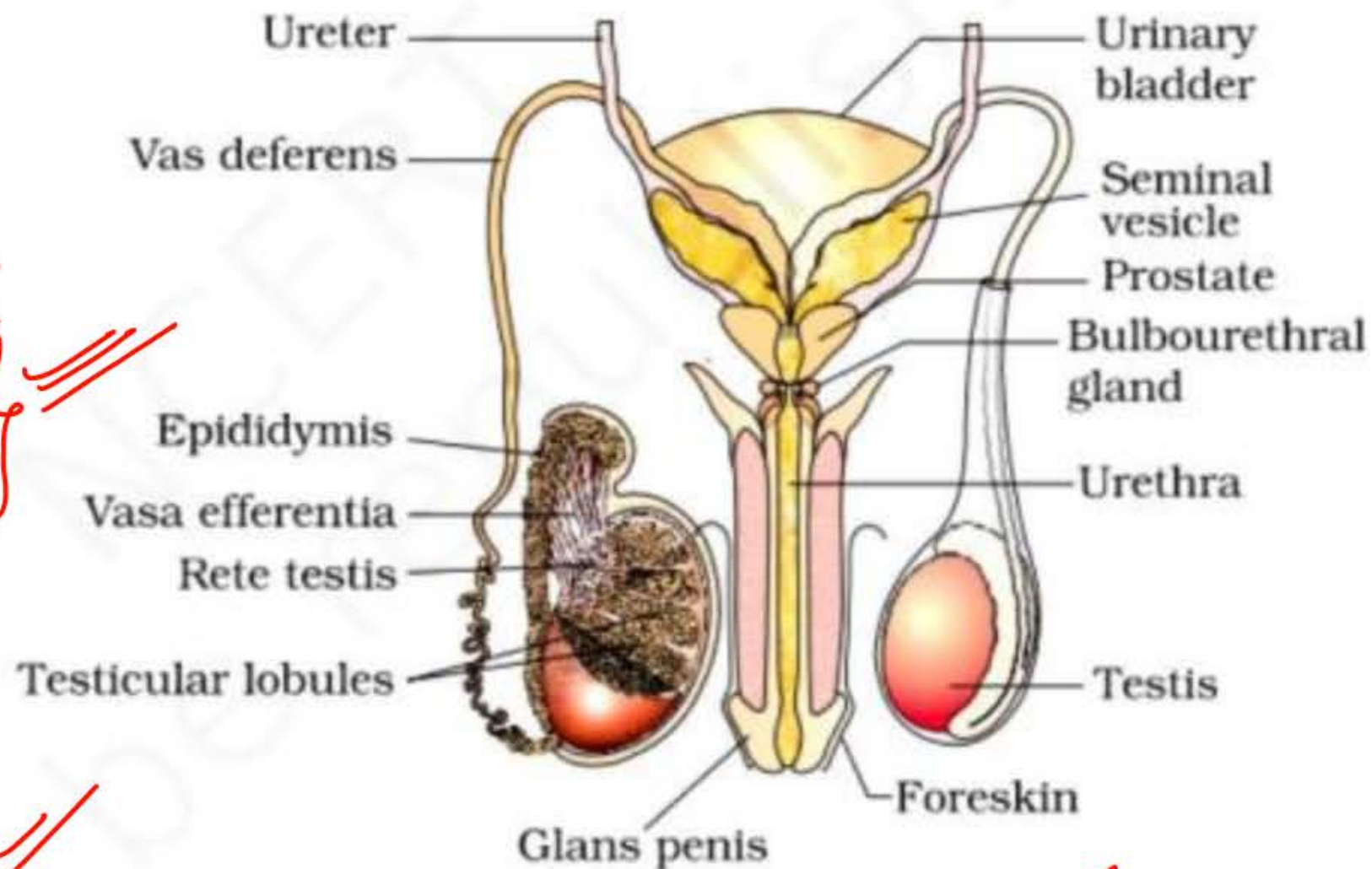


Figure 2.1(b) Diagrammatic view of male reproductive system (part of testis is open to show inner details)

The male sex accessory ducts include **rete testis**, **vasa efferentia**, **epididymis** and **vas deferens** (Figure 2.1b). The seminiferous tubules of the testis open into the vasa efferentia through rete testis. The vasa efferentia leave the testis and open into epididymis located along the posterior surface of each testis. The epididymis leads to vas deferens that ascends to the abdomen and loops over the urinary bladder. It receives a duct from seminal vesicle and opens into urethra as the ejaculatory duct (Figure 2.1a). These ducts store and transport the sperms from the testis to the outside through urethra. The urethra originates from the urinary bladder and extends through the penis to its external opening called **urethral meatus**.

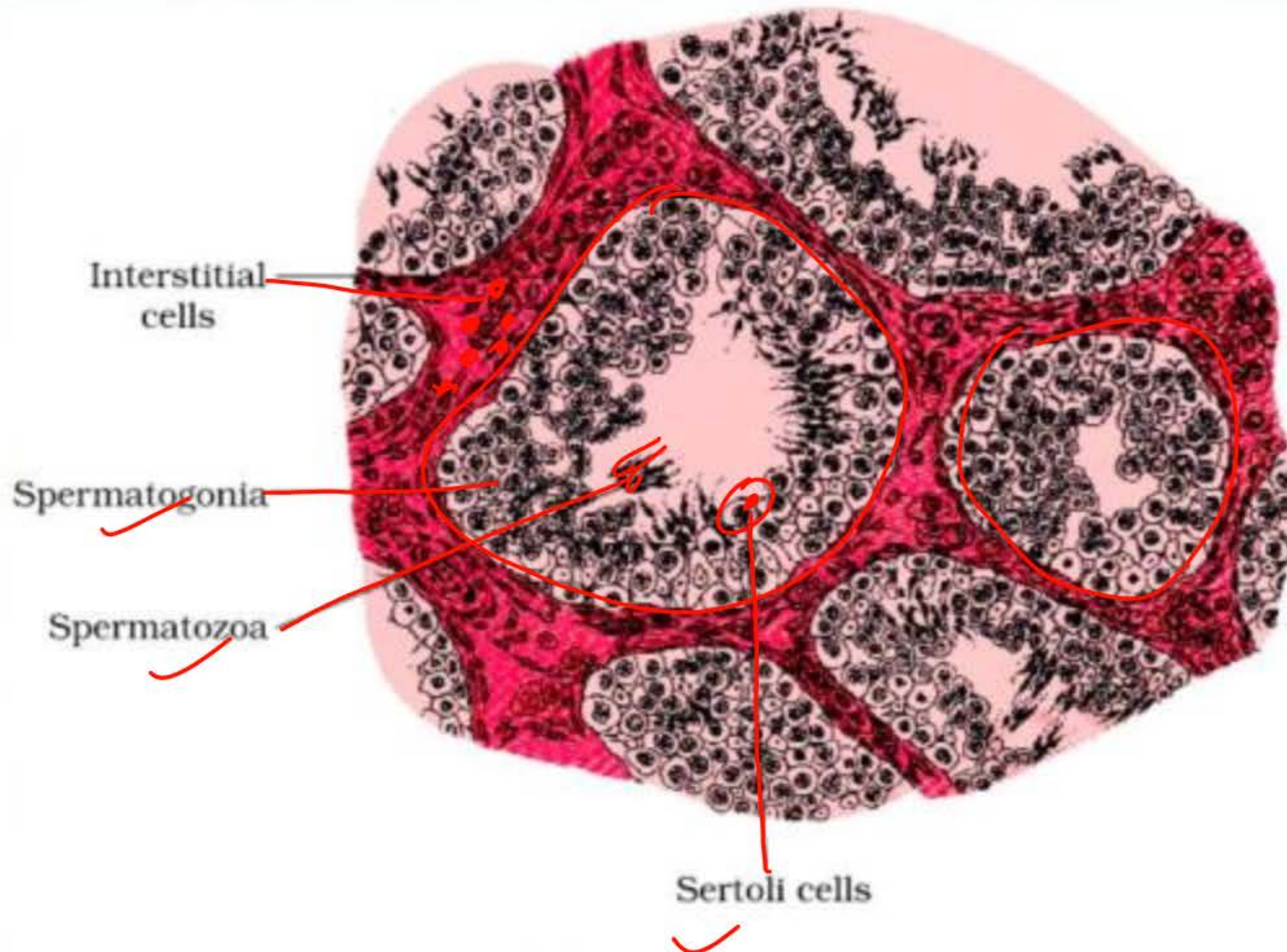


Figure 2.2 Diagrammatic sectional view of seminiferous tubule

———— **FOR NOTES & DPP CHECK DESCRIPTION** ————

AR

The penis is the male external genitalia (Figure 2.1a, b). It is made up of special tissue that helps in erection of the penis to facilitate insemination. The **enlarged** end of penis called the glans penis is covered by a loose fold of skin called **foreskin**.

The male accessory glands (Figure 2.1a, b) include paired **seminal vesicles**, a **prostate** and paired **bulbourethral** glands. Secretions of these glands constitute the seminal plasma which is rich in fructose, calcium and certain enzymes. The secretions of bulbourethral glands also helps in the lubrication of the penis.

Question

Event that does not occur in human reproduction is

False

- A** Insemination ✓
- B** Self-fertilisation ✓
- C** Gestation ✓
- D** Parturition ✓

————— **FOR NOTES & DPP CHECK DESCRIPTION** —————

Question

The male reproductive system includes

- I. Primary sex organ ✓
- II. Accessory duct ✓
- III. Accessory glands ✓
- IV. External genitalia ✓

- A** I, II and III
- B** I, III and IV
- C** I and IV only
- D** All of the above ✓

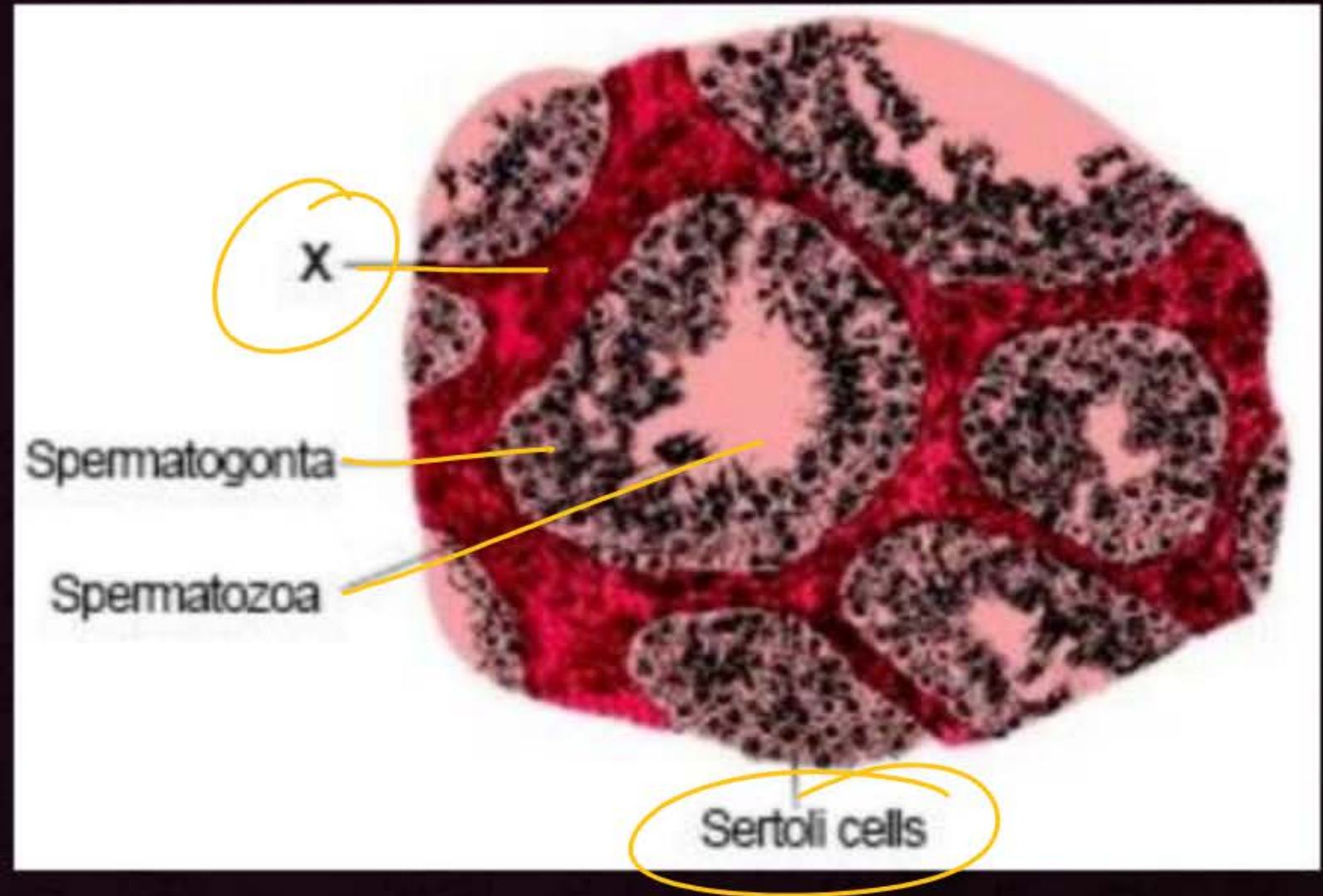
————— **FOR NOTES & DPP CHECK DESCRIPTION** —————

Question



Identify the structure X

- A** Sertoli Cells
- B** Spermatogonia
- C** Interstitial Cells
- D** Phagocytic cells



————— **FOR NOTES & DPP CHECK DESCRIPTION** —————

Question

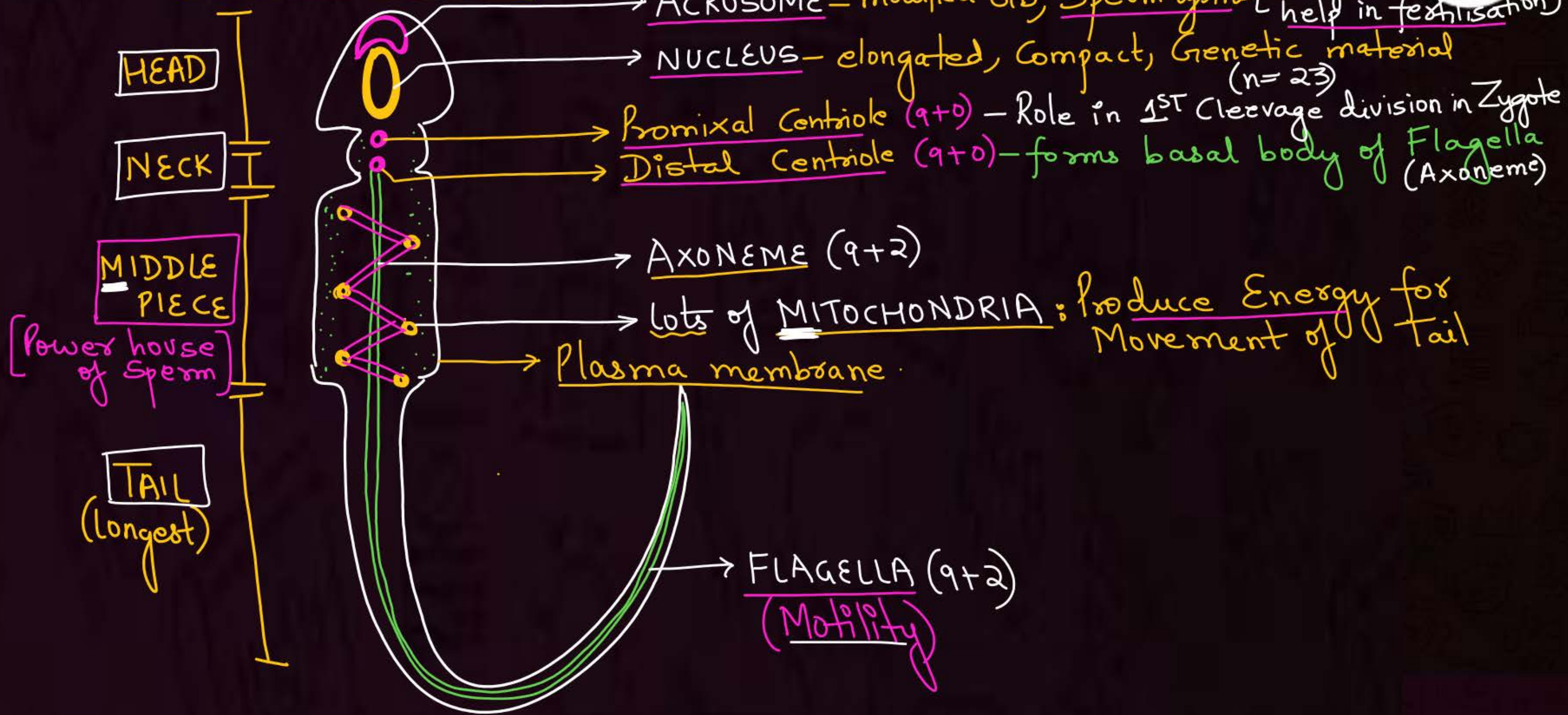
Which of the following is not paired structure?

- A** Seminal vesicle 2
- B** Ejaculatory duct 2
- C** Cowper's Gland 2
- D** Prostate Gland 1

———— FOR NOTES & DPP CHECK DESCRIPTION ————



* HUMAN SPERM :-





* Normal Semen → At least 60% Normal Shape & Size
→ At least 40% Vigorous motility
(Forty) (Fast)



Female Reproductive System

① Sex Organ = Gonad

OVARY

- Produce ♀ Gamete (steroidal)
- Produce ♀ Sex hormones
[Progesterone, Estrogen]

⑤ Sex Organs

Accessory Ducts

1. Fallopian Tube / Oviduct
2. Uterus
3. Cervix
4. Vagina

External Genitalia

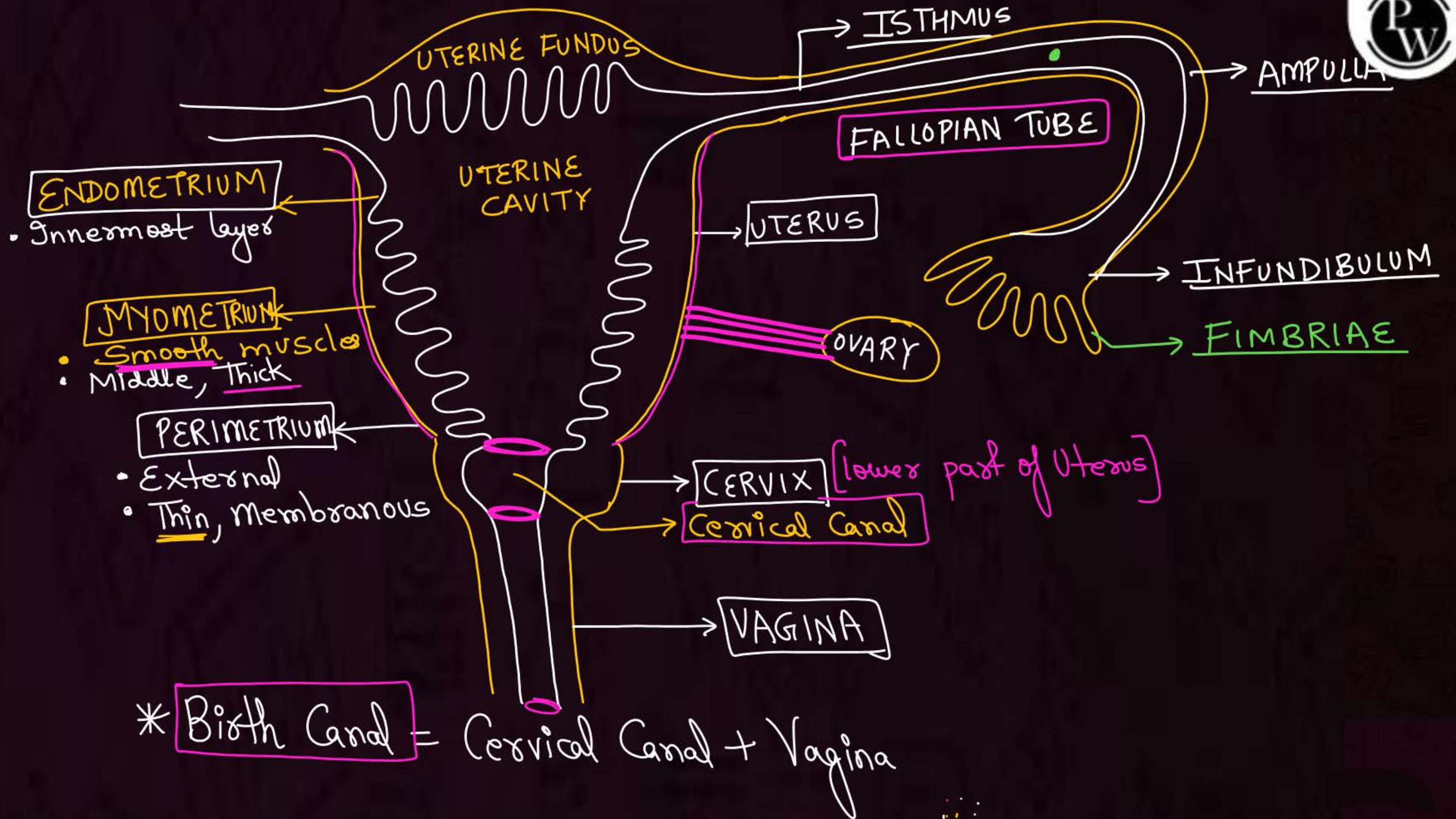
1. Mons pubis Maths
2. Clitoris Chem.
3. Labia Lengthy
(Majora, Minora)
4. Hymen Hai

Accessory Glands

1. Mammary Glands

In PELVIC Region

Integrate Structurally and Functionally to Support
Ovulation, Fertilisation, Pregnancy, delivery, Child care (Lactation)





• from Periphery of each ovary to Uterus

OVARY

- ✓ 1 Pair
- ✓ One on each side of lower abdomen
- ✓ 2-4 cm (Length)
- ✓ Connected to Uterus and Pelvic wall by ligaments
- ✓ Primary Sex Organ

Fallopian tube

1 Pair
Ciliated Columnar Epithelium

- 10-12 cm long
- 3 Parts:

1) Infundibulum

- ✓ Closest to Ovary
- ✓ Finger-like projections, FIMBRIAE (collect Ovum after Ovulation)

2) AMPULLA — widest part

3) ISTHMUS

narrow last part
Opens into Uterus

* Site of Fertilisation

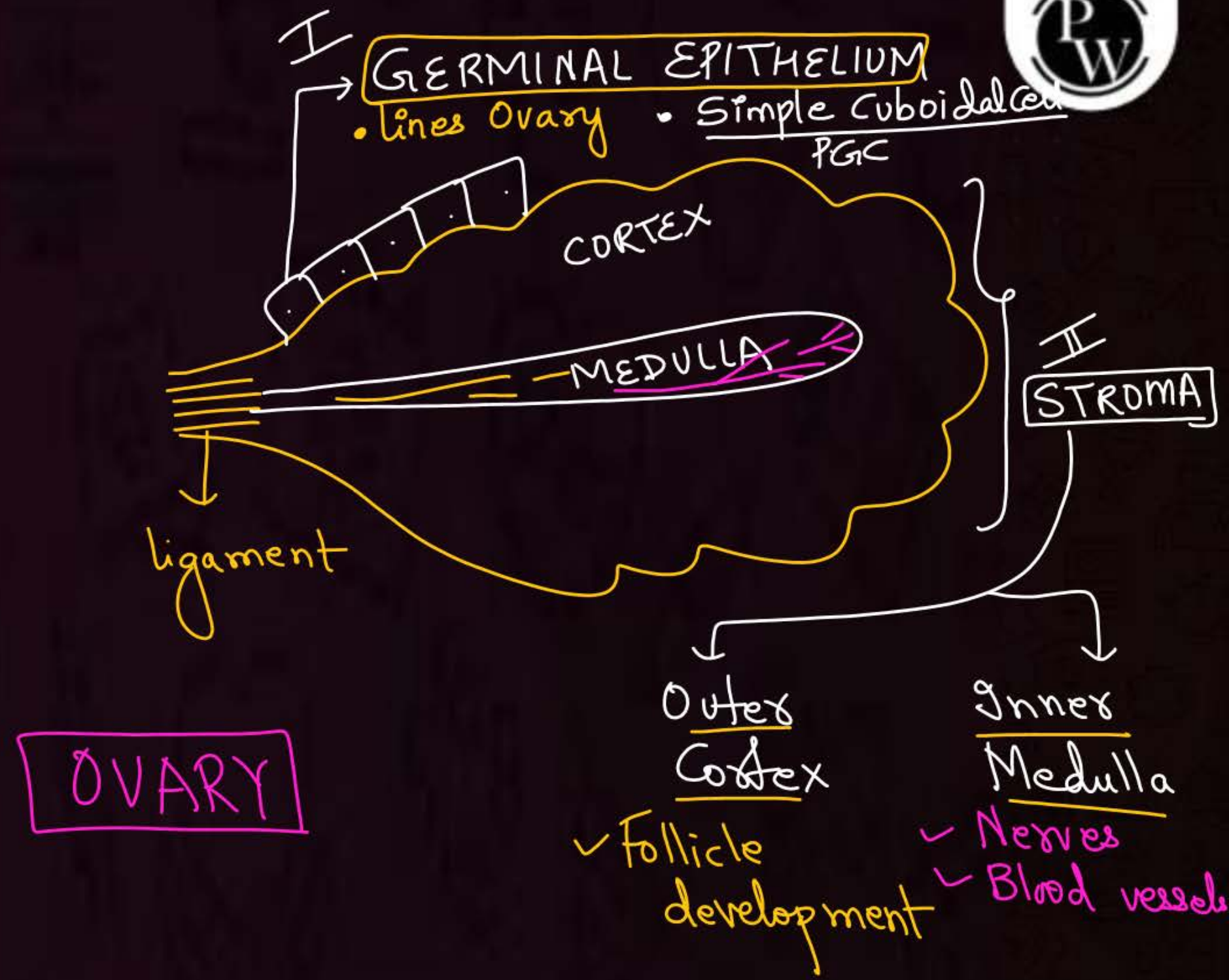
1. Ampullary-Isthmic junction (NCERT Summary)
2. Ampulla (NCERT Theory)

UTERUS WOMB

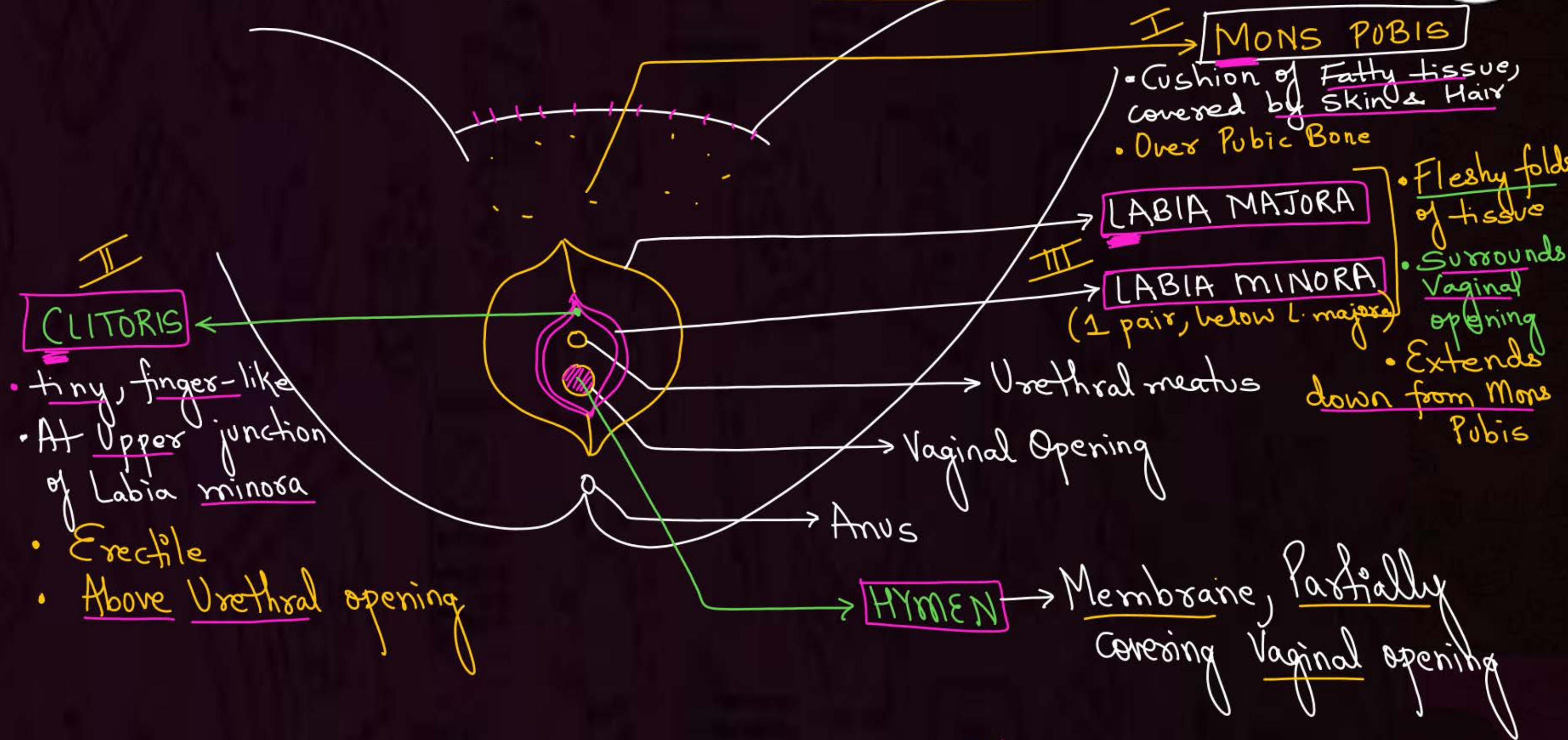
- Inverted Pear shaped
- Single
- opens into Vagina through Cervix
- Connected to pelvic wall by ligaments
- Uterine Wall: 3 layers
 - a) Perimetrium
 - b) Myometrium — Strong Contractions during childbirth
 - c) Endometrium
 - Implantation of Blastocyst
 - Cyclic changes during menstrual cycle
 - Glandular
 - lines Uterine Cavity

VAGINA

- Copulatory Organ
- NKSSSE



FEMALE EXTERNAL GENITALIA



2.2 THE FEMALE REPRODUCTIVE SYSTEM

The female reproductive system consists of a pair of **ovaries** alongwith a pair of **oviducts, uterus, cervix, vagina** and the **external genitalia** located in pelvic region (Figure 2.3a). These parts of the system alongwith a pair of the **mammary glands** are integrated structurally and functionally to support the processes of ovulation, fertilisation, pregnancy, birth and child care.

AR Ovaries are the primary female sex organs that produce the female gamete (ovum) and several steroid hormones (ovarian hormones). The ovaries are located one on each side of the lower abdomen (Figure 2.3b). Each ovary is about 2 to 4 cm in length and is connected to the pelvic wall and uterus by ligaments. Each ovary is covered by a thin epithelium which encloses the ovarian stroma. The stroma is divided into two zones – a peripheral cortex and an inner medulla.

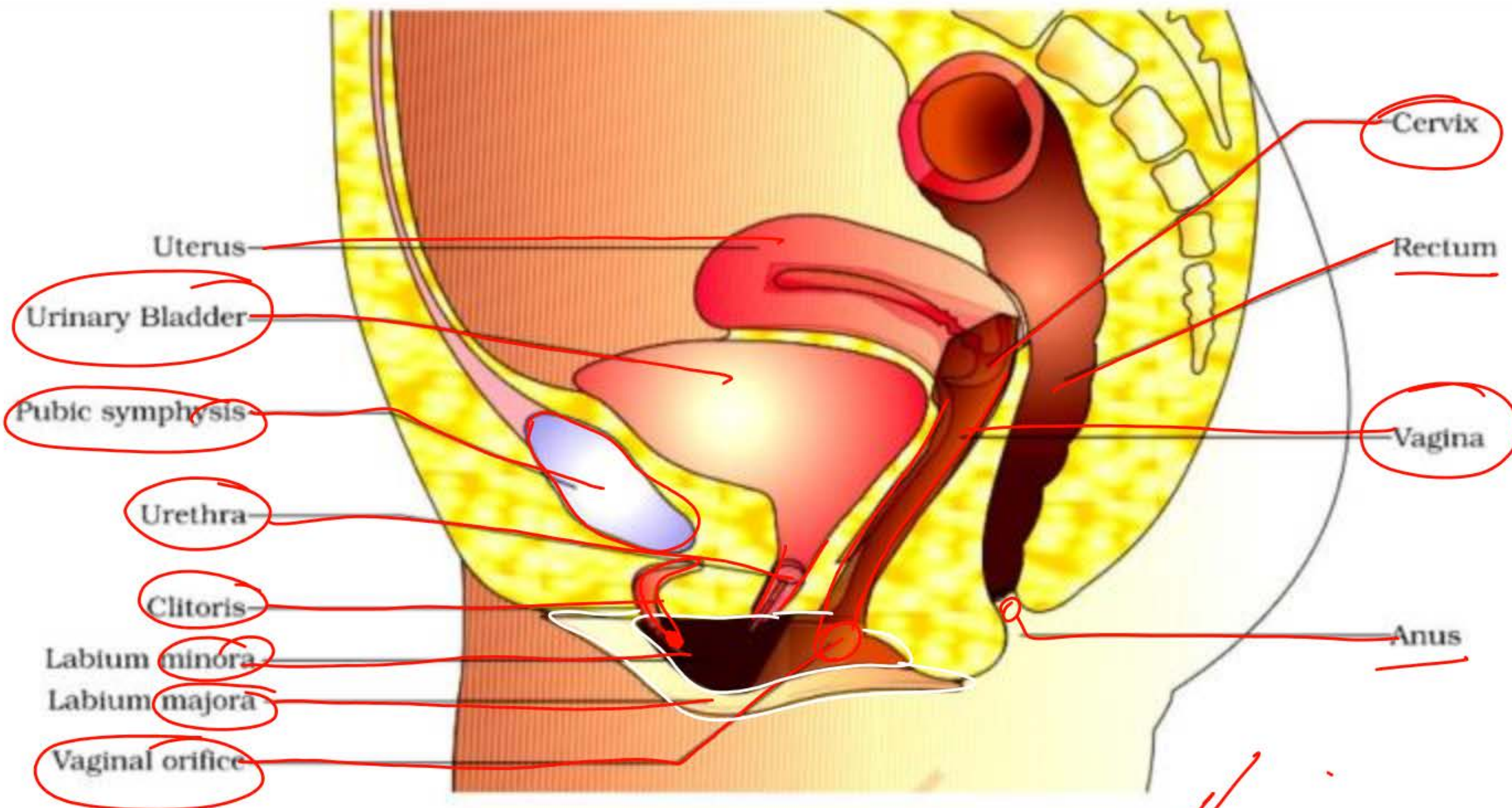


Figure 2.3 (a) Diagrammatic sectional view of female pelvis showing reproductive system

FOR NOTES & DPP CHECK DESCRIPTION

The oviducts (fallopian tubes), uterus and vagina constitute the female accessory ducts. Each fallopian tube is about 10-12 cm long and extends from the periphery of each ovary to the uterus (Figure 2.3b), the part closer to the ovary is the funnel-shaped **infundibulum**. The edges of the infundibulum possess finger-like projections called **fimbriae**, which help in collection of the ovum after ovulation. The infundibulum leads to a wider

AR

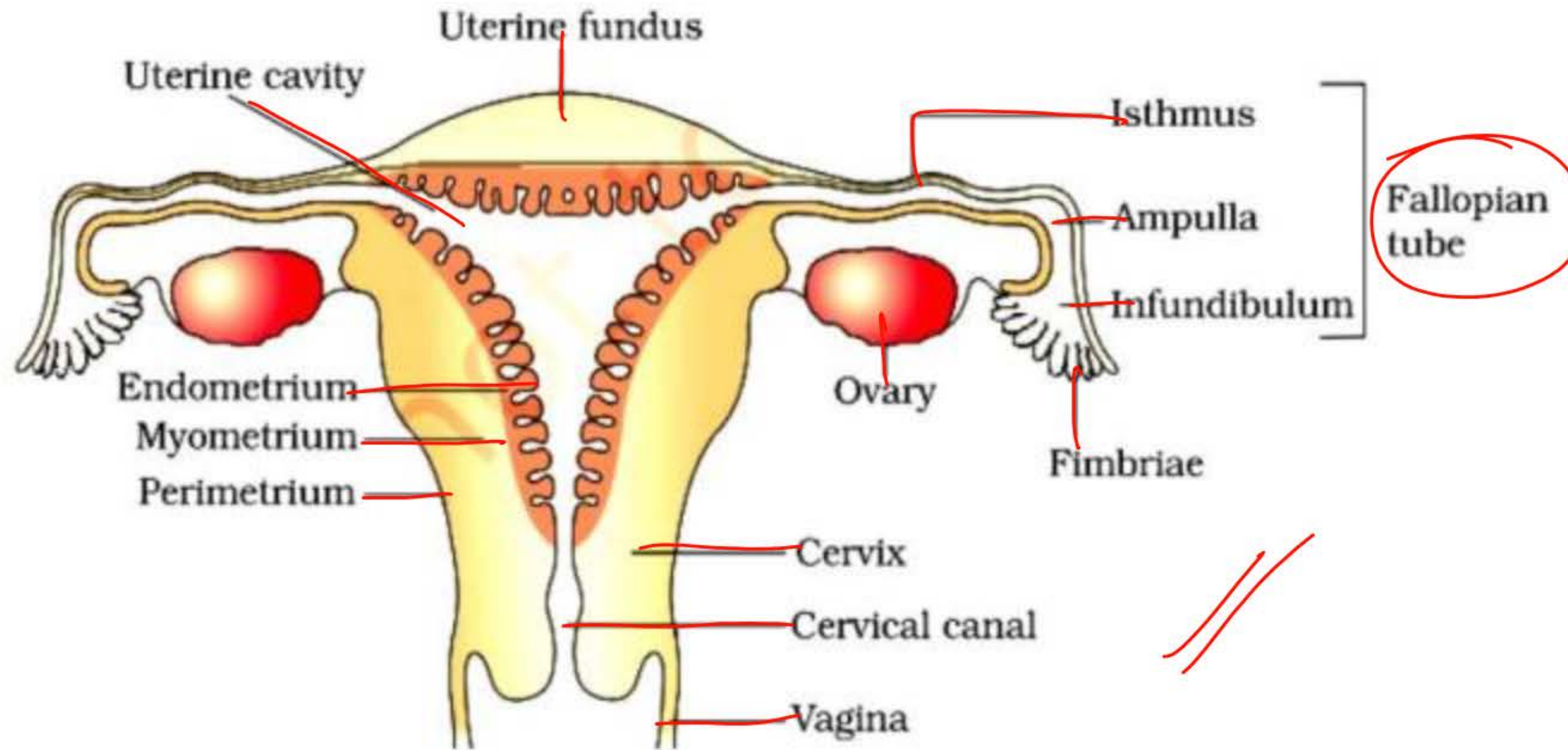


Figure 2.3 (b) Diagrammatic sectional view of the female reproductive system

————— **FOR NOTES & DPP CHECK DESCRIPTION** —————

part of the oviduct called **ampulla**. The last part of the oviduct, **isthmus** has a narrow lumen and it joins the uterus.

The uterus is single and it is also called **womb**. The shape of the uterus is like an inverted pear. It is supported by ligaments attached to the pelvic wall. The uterus opens into vagina through a narrow cervix. The cavity of the cervix is called **cervical canal** (Figure 2.3b) which alongwith vagina forms the birth canal. The wall of the uterus has three layers of tissue. The external thin membranous **perimetrium**, middle thick layer of smooth muscle, **myometrium** and inner glandular layer called **endometrium** that lines the uterine cavity. The endometrium undergoes cyclical changes during menstrual cycle while the myometrium exhibits strong contraction during delivery of the baby.

The female external genitalia include mons pubis, labia majora, labia minora, hymen and clitoris (Figure 2.3a). **Mons pubis** is a cushion of fatty tissue covered by skin and pubic hair. The **labia majora** are fleshy folds of tissue, which extend down from the mons pubis and surround the vaginal opening. The **labia minora** are paired folds of tissue under the labia majora. The opening of the vagina is often covered partially by a membrane called **hymen**. The **clitoris** is a tiny finger-like structure which lies at the upper junction of the two labia minora above the urethral opening. The hymen is often torn during the first coitus (intercourse). *However, it can also be broken by a sudden fall or jolt, insertion of a vaginal tampon, active participation in some sports like horseback riding, cycling, etc. In some women the hymen persists even after coitus. In fact, the presence or absence of hymen is not a reliable indicator of virginity or sexual experience.*

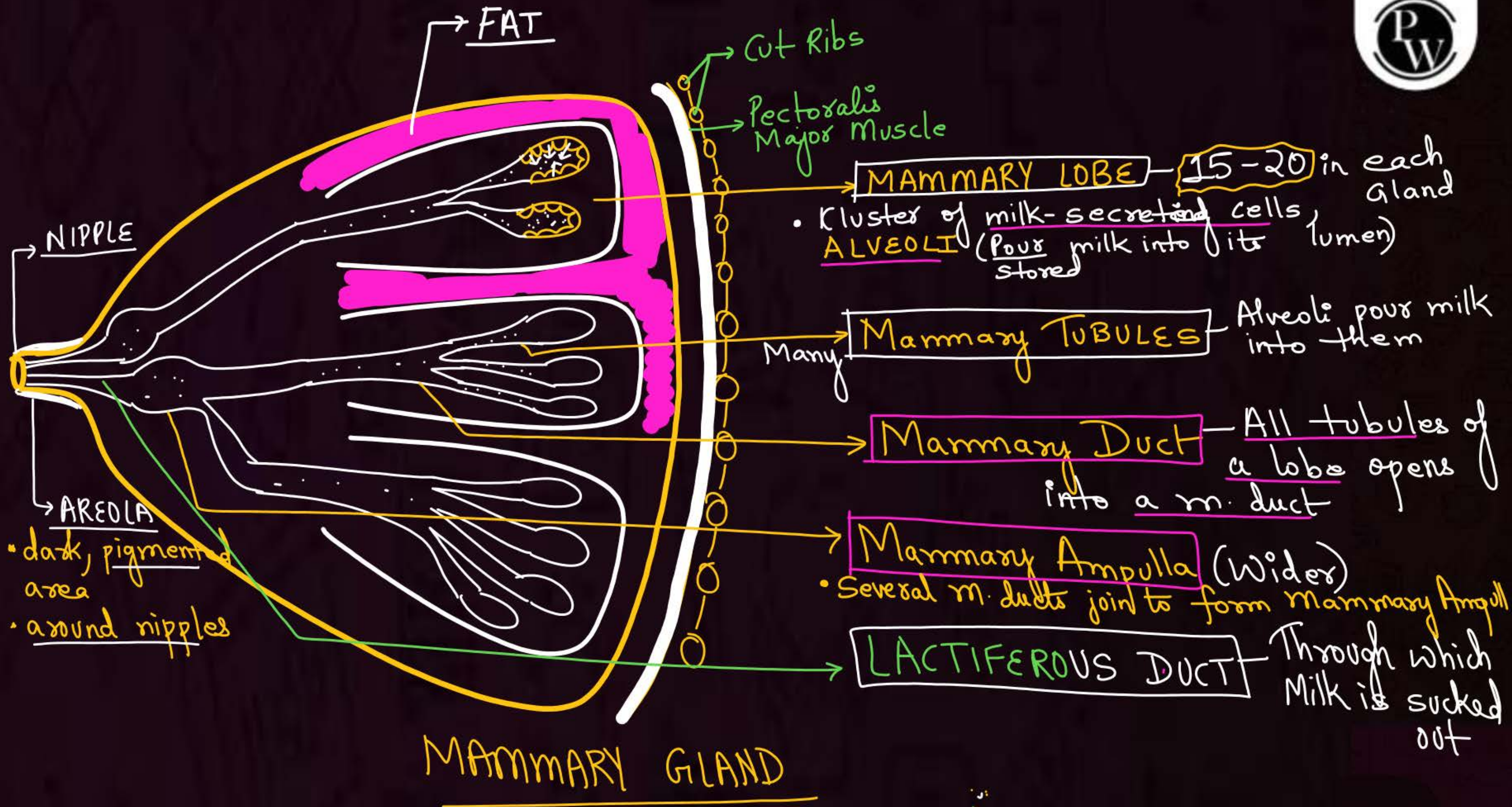
AR

H.W.
Add
in
Notes



* MAMMARY GLAND

- Character of ♀ Mammals
- 1 pair
- To nourish Newborn
- Glandular Part + Fat (Variable)



Passage of Milk

Many alveoli ✓



Many mammary tubules ✓



One mammary duct ✓✓

Several mammary ducts joins to form



Lactiferous Sinus/Mammary Ampulla ✓✓
(Dilated part, just before nipple)



Lactiferous Duct ✓✓
Opens outside through nipple

————— FOR NOTES & DPP CHECK DESCRIPTION —————

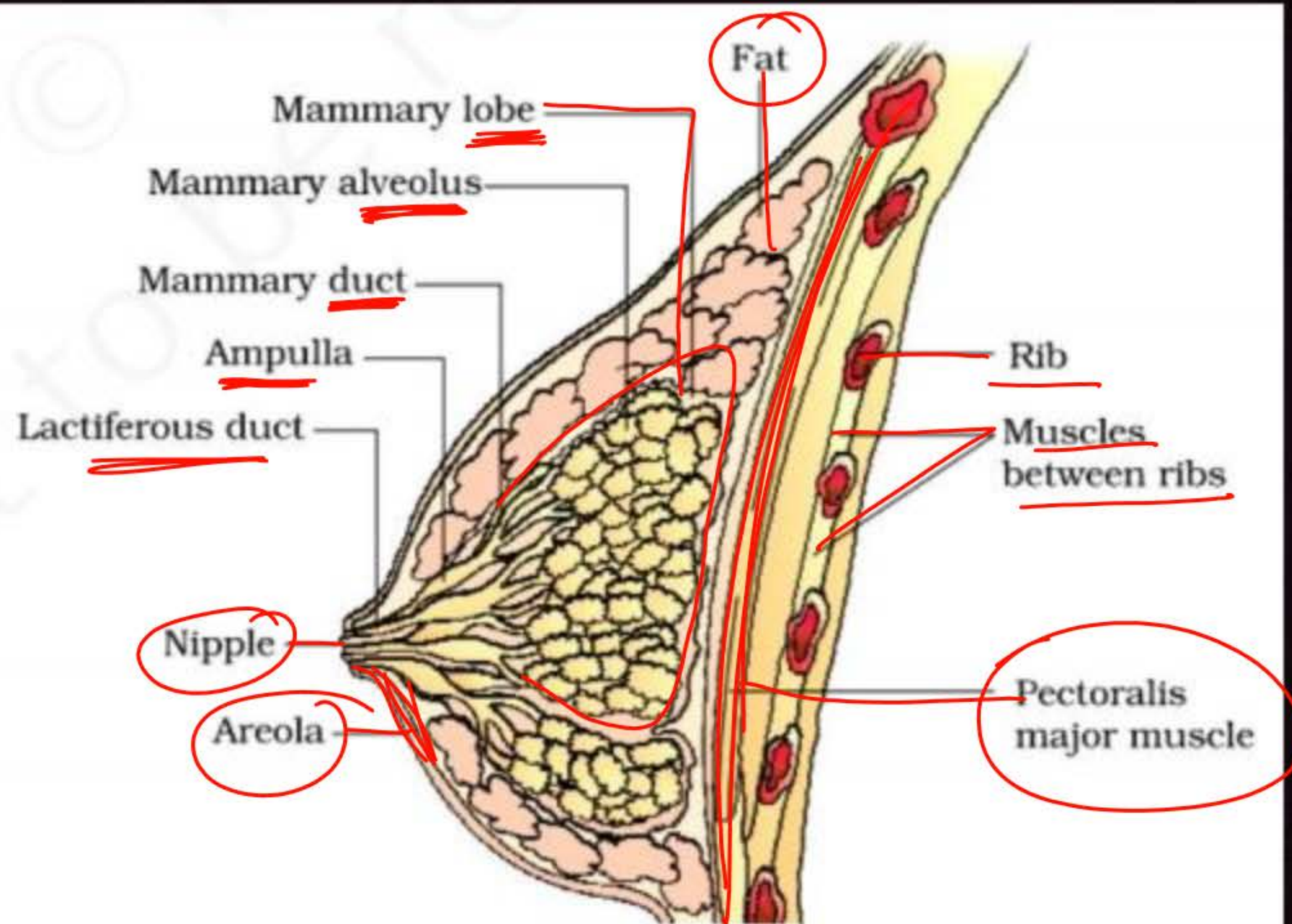


Figure 2.4 A diagrammatic sectional view of Mammary gland

———— **FOR NOTES & DPP CHECK DESCRIPTION** ————

A functional mammary gland is characteristic of all female mammals. The mammary glands are paired structures (breasts) that contain glandular tissue and variable amount of fat. The glandular tissue of each breast is divided into 15-20 **mammary lobes** containing clusters of cells called alveoli (Figure 2.4). The cells of alveoli secrete milk, which is stored in the cavities (lumens) of alveoli. The alveoli open into mammary tubules. The tubules of each lobe join to form a **mammary duct**. Several mammary ducts join to form a wider mammary ampulla which is connected to **lactiferous duct** through which milk is sucked out.

Question



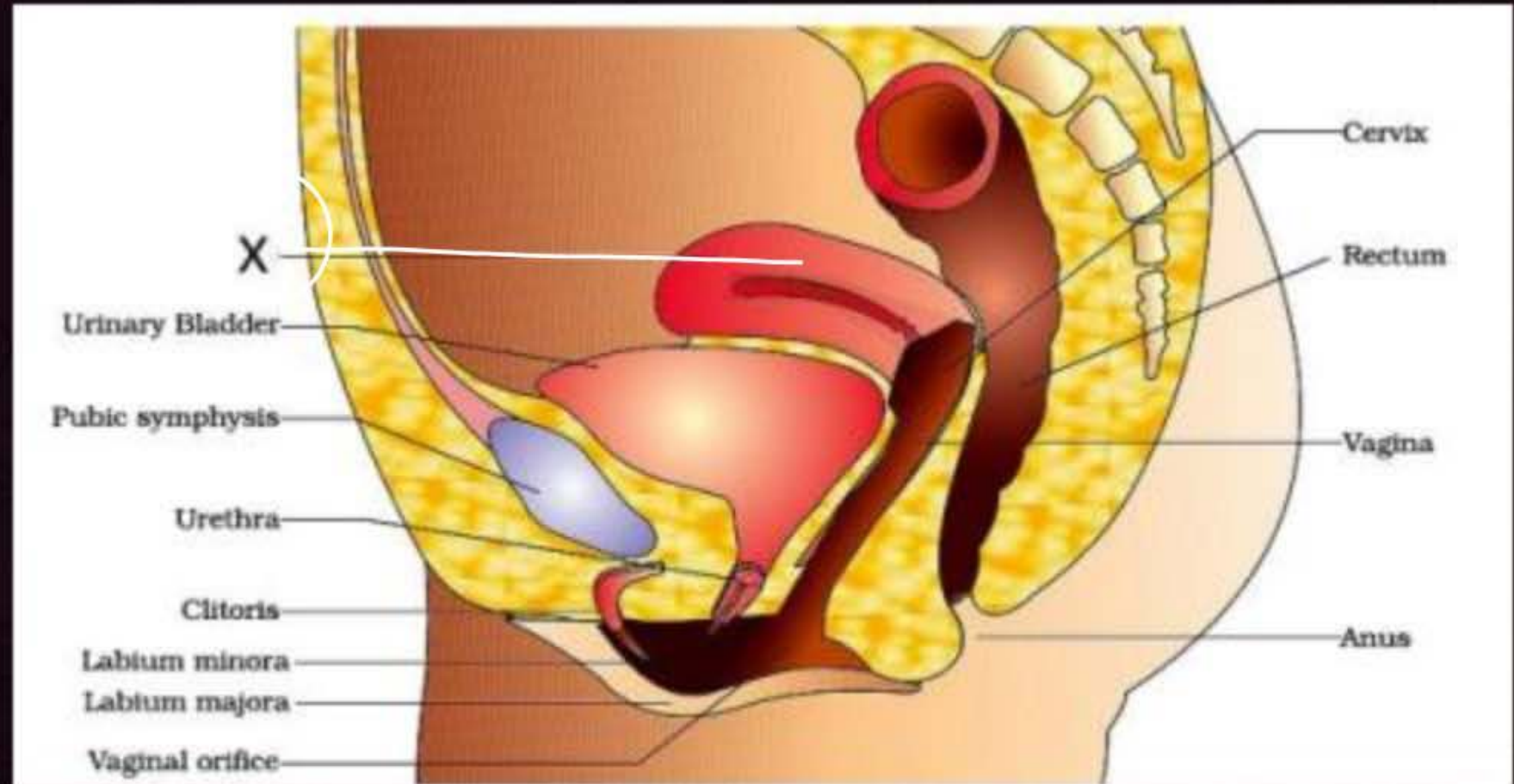
Identify the structure X

A Urinary Bladder

B Rectum

C ☒ Uterus

D Vagina



————— **FOR NOTES & DPP CHECK DESCRIPTION** —————

Question



Identify A, B, C and D correctly.

A

A – Ovary
B – Vagina
C – Infundibulum
D – Uterine fundus

B

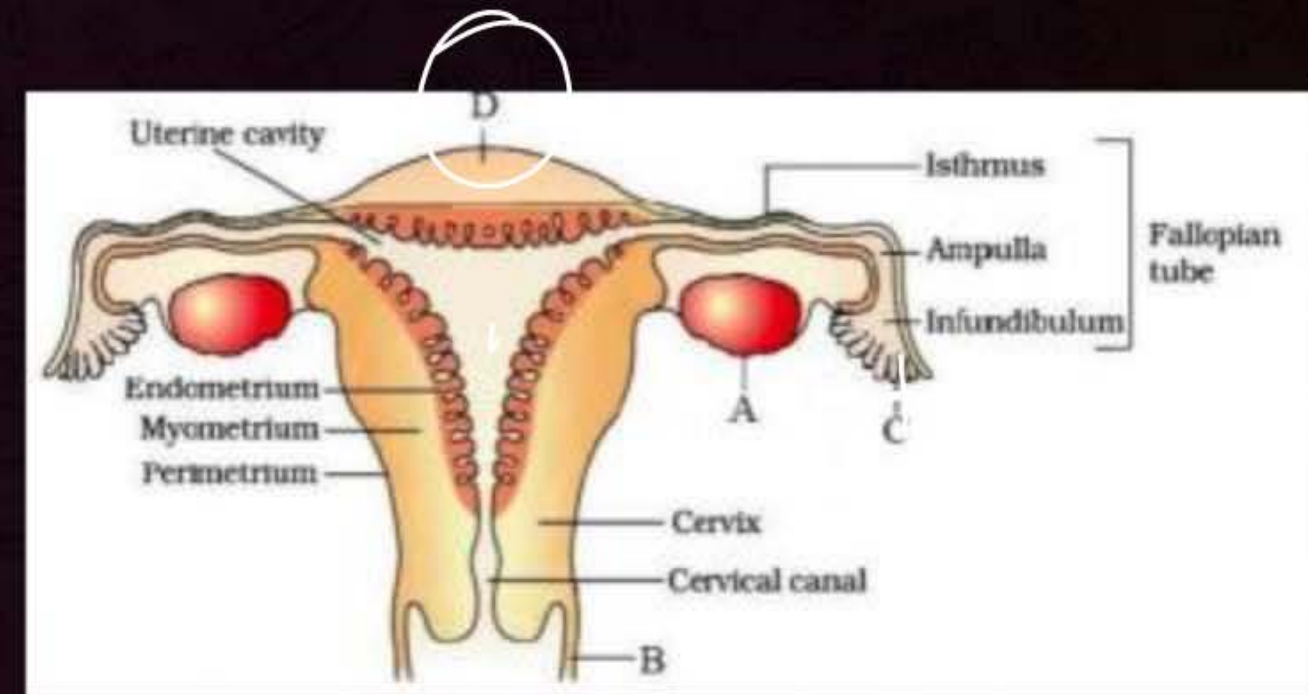
A – Ovary
B – Vagina
C – Fimbriae
D – Uterine fundus

C

A – Ovary
B – Vagina
C – Fimbriae
D – Uterine cavity

D

A – Ovary
B – Cervix
C – Fimbriae
D – Uterine fundus



————— FOR NOTES & DPP CHECK DESCRIPTION —————

Question



Match the structure with their function

A ~~a - iii, b - iv, c - i, d - ii~~

B ~~a - iv, b - iii, c - i, d - ii~~

C ~~a - ii, b - iv, c - i, d - iii~~

D ~~a - i, b - iv, c - iii, d - ii~~

| | | | |
|----|----------|-------|-------------------|
| a. | Uterus | (i) | Fertilisation |
| b. | Vagina | (ii) | Gamete production |
| c. | Oviducts | (iii) | Implantation |
| d. | Ovaries | (iv) | Insemination |

————— FOR NOTES & DPP CHECK DESCRIPTION —————

Question

The opening of the "X" is often covered partially by a membrane called "Y". The "Y" is often torn during the first coitus (intercourse). Identify "X" and "Y".

- ☐ **A** X – uterus; Y – hymen
- ☐ **B** X – vagina; Y – birth canal
- ☒ **C** X – vagina; Y – hymen
- ☐ **D** X – cervix; Y – hymen

————— **FOR NOTES & DPP CHECK DESCRIPTION** —————

Question

How many factors from given below in the box can be included as causes of tear of hymen?

sudden fall, insertion of a vaginal tampon, cycling, first coitus, sneezing

A Three

B Four

C Two

D One

————— **FOR NOTES & DPP CHECK DESCRIPTION** —————

Question



Read the following statements and find out the correct statements.

- I. The opening of the vagina is ~~wholly~~ covered by a membrane called hymen.
- II. The labia minora are under the labia majora.
- III. The clitoris is a tiny finger-like structure ~~below~~ ^{above} the urethral opening.
- IV. The clitoris lies at the upper junction of the two labia minora.

A I, II and III only

B ~~II, III and IV only~~

C II and IV only

D I, II and IV only

————— **FOR NOTES & DPP CHECK DESCRIPTION** —————

Question



Statement-I: Labia minora extend down from the mons pubis. ~~X~~

Statement-II: The opening of the vagina is often covered partially by the hymen. ✓

- A** Statement I and Statement II both are correct. ~~X~~
- B** Statement I is correct, but Statement II is incorrect. ~~X~~
- C** Statement I is incorrect, but Statement II is correct. ✓
- D** Statement I and Statement II both are incorrect. ~~X~~

————— **FOR NOTES & DPP CHECK DESCRIPTION** —————

Question



~~Statement-I: Hymen is a reliable indicator of sexual experience.~~

~~Statement-II: In women, the hymen always torn during the first coitus (intercourse).~~

- ~~A~~ Statement I and Statement II both are correct. *often*
- ~~B~~ Statement I is correct, but Statement II is incorrect.
- ~~C~~ Statement I is incorrect, but Statement II is correct.
- ☒ ~~D~~ Statement I and Statement II both are incorrect.

————— **FOR NOTES & DPP CHECK DESCRIPTION** —————

Question



Assertion (A): The presence or absence of hymen is not a reliable indicator of virginity.

Reason (R): The hymen can also be broken by a sudden fall, active participation in some sports like horseback riding, cycling, etc.

That's why

- A** Both Assertion (A) and Reason (R) are true, and Reason (R) is a correct explanation of Assertion (A).
- B** Both Assertion (A) and Reason (R) are true, but Reason (R) is ~~not~~ a correct explanation of Assertion (A).
- C** Assertion (A) is true, and Reason (R) is ~~false~~.
- D** Assertion (A) is ~~false~~, and Reason (R) is true.

————— **FOR NOTES & DPP CHECK DESCRIPTION** —————

Question



The mammary glands are paired structures (breasts) that contain _____(X)_____and_____ (Y).

Choose the option which fills the blanks correctly.

- A** (X): non-~~glandular~~ tissue, (Y): variable amount of fat
- B** (X): glandular tissue, (Y): variable amount of areolar ~~tissue~~
- C** (X): non-~~glandular~~ tissue, (Y): variable amount of areolar tissue
- D** ~~(X):~~ glandular tissue, (Y): variable amount of fat

————— **FOR NOTES & DPP CHECK DESCRIPTION** —————

Question

Choose the option with correct sequence.

- A. Mammary lobes
- B. Mammary ducts
- C. Lactiferous duct
- D. Mammary ampulla
- E. Mammary tubules

$A \rightarrow E \rightarrow B \rightarrow D \rightarrow C$

A ~~$A \rightarrow B \rightarrow C \rightarrow D \rightarrow E$~~

B ~~$B \rightarrow C \rightarrow D \rightarrow A \rightarrow E$~~

C $A \rightarrow E \rightarrow B \rightarrow D \rightarrow C$

D ~~$C \rightarrow E \rightarrow D \rightarrow B \rightarrow A$~~

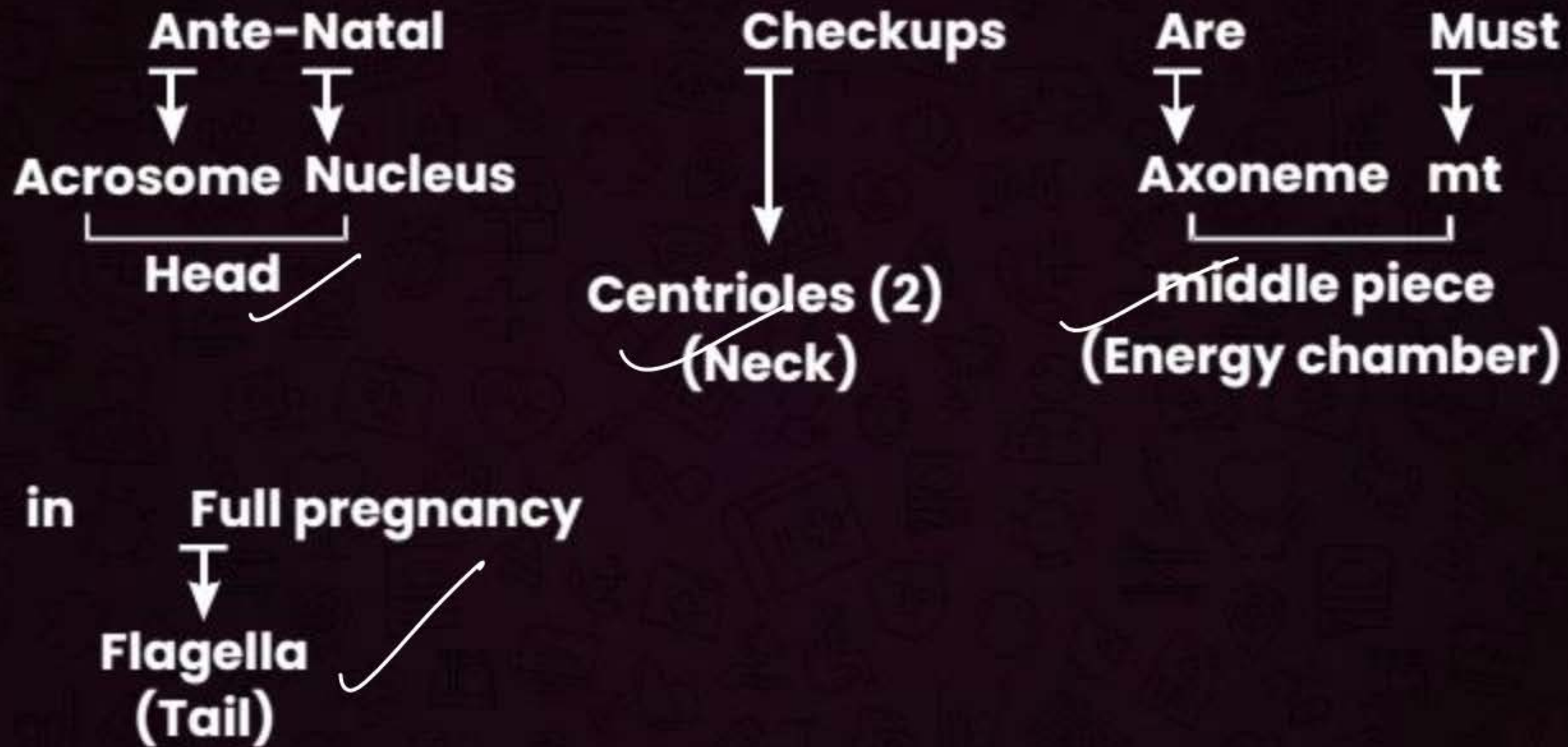
———— **FOR NOTES & DPP CHECK DESCRIPTION** ————

Spermatogonia

- 1 primary spermatocyte (2n) – 2 secondary spermatocyte
- 1 secondary spermatocyte – 2 spermatid(n)
- 1 secondary spermatocyte(n) – 2 sperm(n)
- 1 primary spermatocyte – 4 sperms
- 1 primary spermatocyte – 4 spermatid(n)

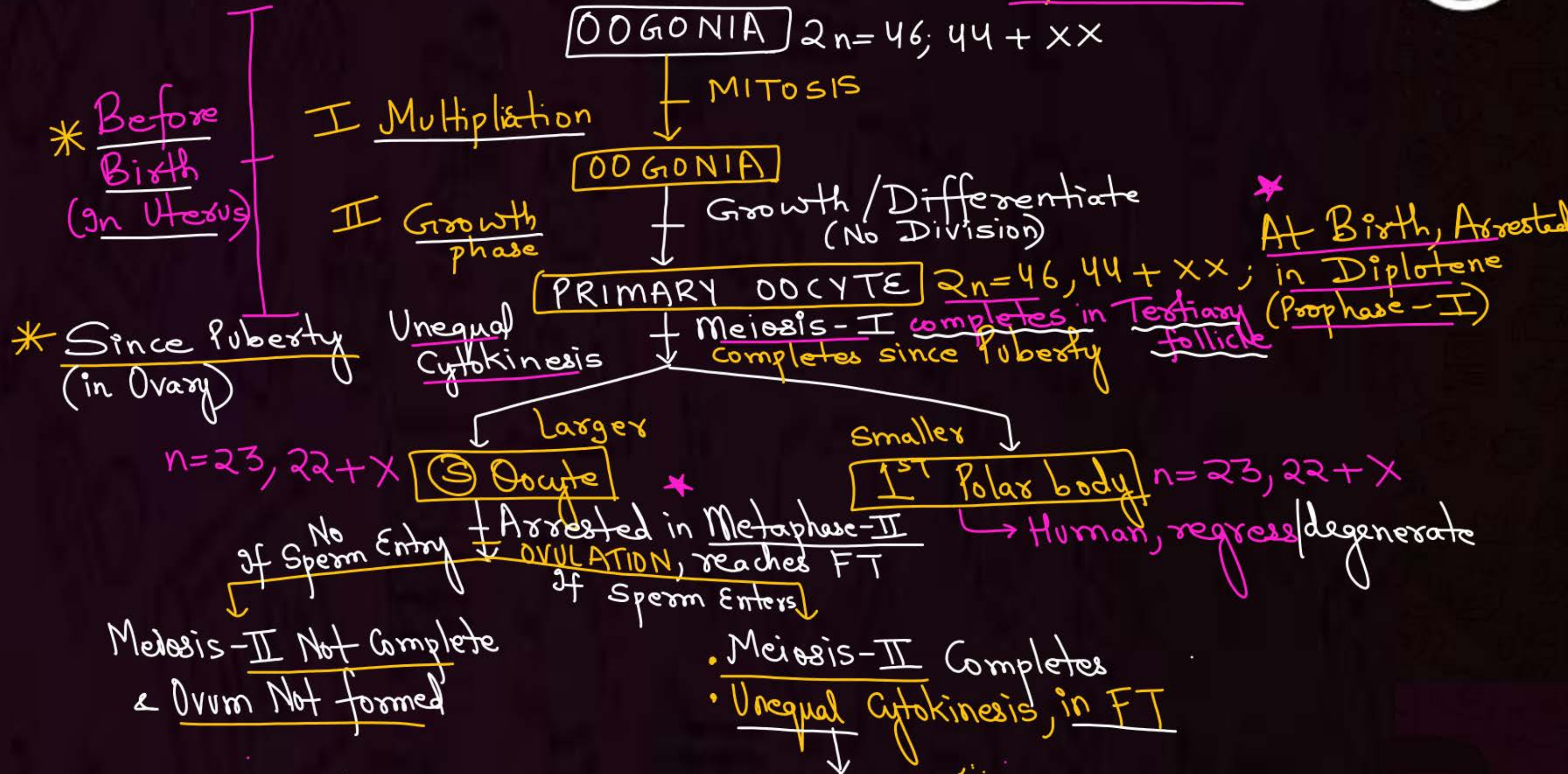
————— **FOR NOTES & DPP CHECK DESCRIPTION** —————

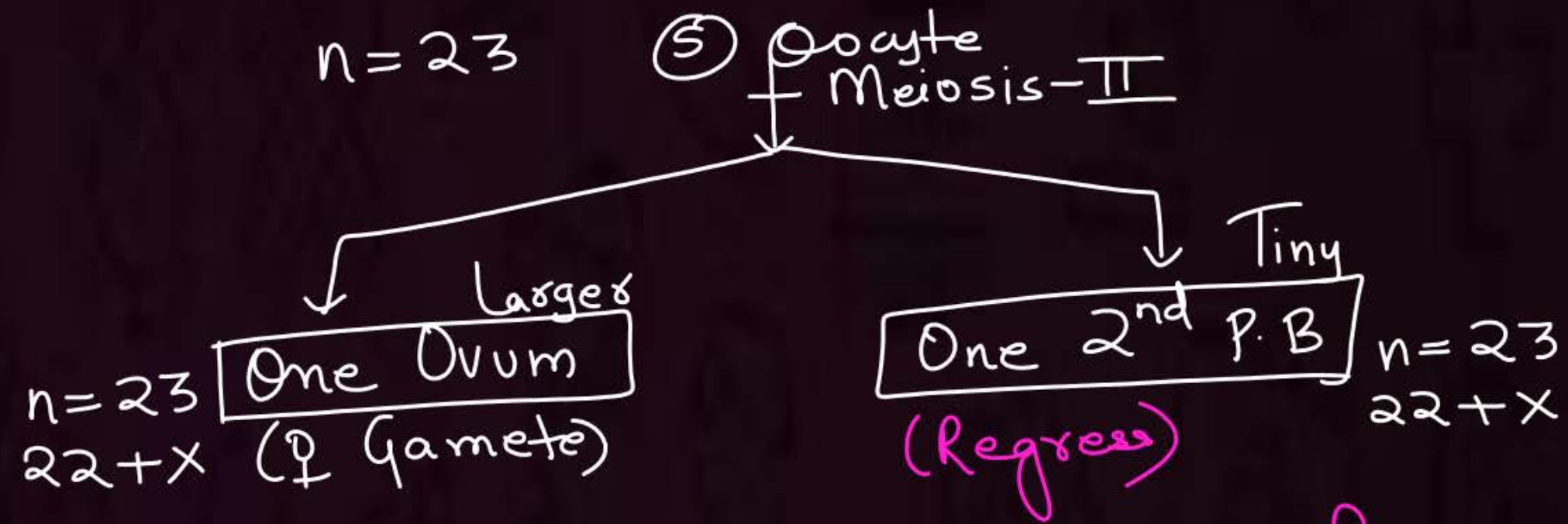
Trick for human sperm



———— **FOR NOTES & DPP CHECK DESCRIPTION** ————

OOGENESIS — Starts In-Utero/Embryonic life/ Before Birth





PYQ * Meiosis-II completed, After Sperm Entry
But Before Fertilisation

* (5) Oocyte and 1st P.B produced every month.

* 2nd P.B and Ovum, Only if fertilisation occurs
Pregnancy

Ques. A female aged 30 yr; Puberty at 16 yr;
a) Calculate no. of Ova produced?

Ans → Zero.

b) No. of Ovulation / ? ⑤ oocyte / 1st P.B ?

$$\begin{array}{l} 30 \text{ yr} - 16 \text{ yr} = 14 \text{ yr} \cdot \times 12 = \boxed{168 \text{ months}} \\ \text{(Age)} \quad \text{(Puberty)} \quad \text{Rep. Active} \end{array}$$
 Ans → 168



Ques: A female aged 32 yr, Puberty 16 yr age.
She has One child.

a) Calculate no. of $\frac{1^{st} \text{ P.B.} / 2^{nd} \text{ oocyte}}{32 - 16 = 16 \text{ yrs} \times 12 = 192 \text{ months} - 15}$
 $= 177$

$\frac{9 \text{ months preg.}}{+ \frac{6 \text{ months Lactation}}{= 15 \text{ months/preg Anovulation}}}$

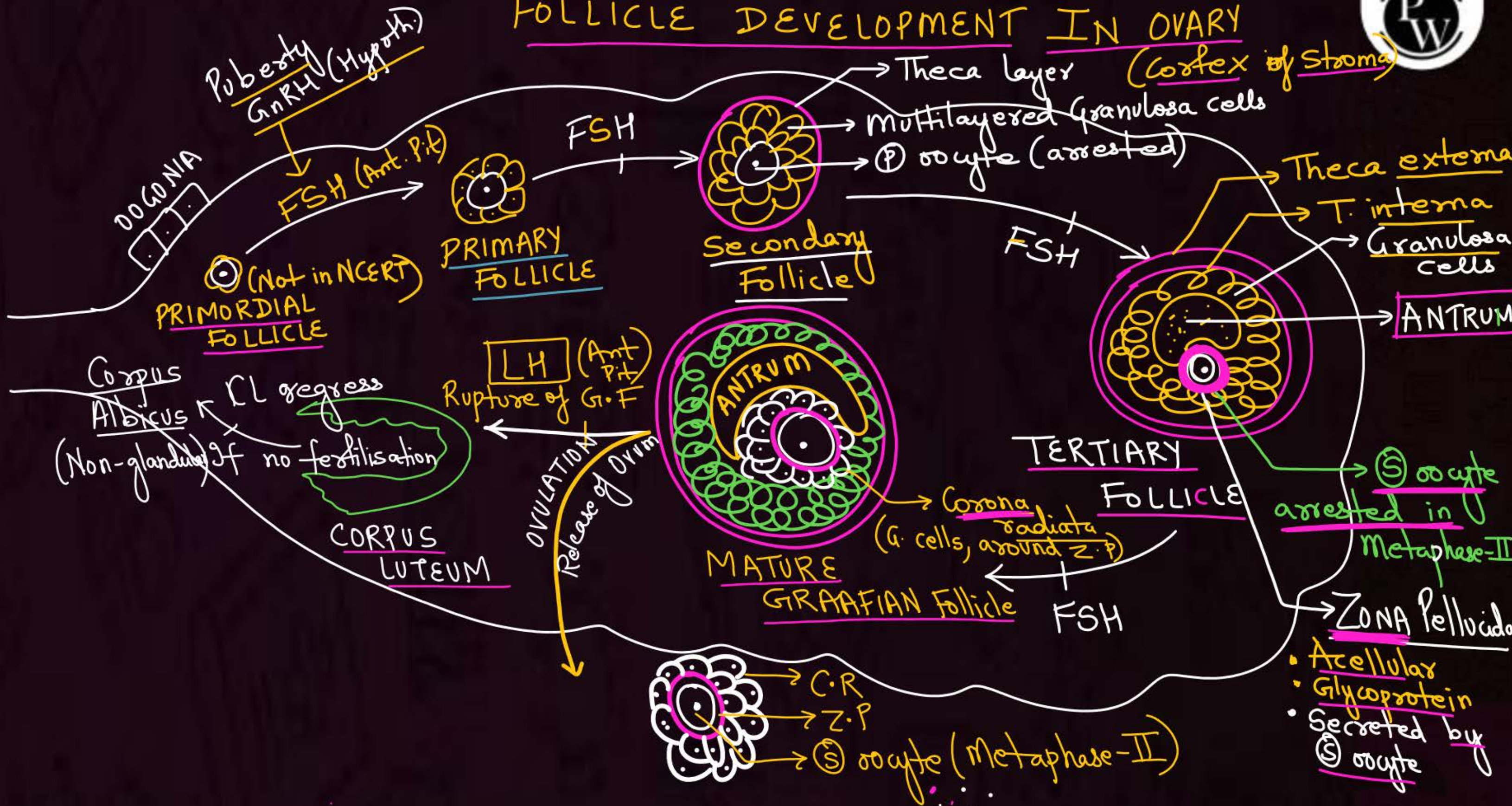
b) No. of $\frac{2^{nd} \text{ P.B.}}{\longrightarrow \text{One}}$

c) $\frac{\text{No. of Total P.B.}}{\longrightarrow 177 + 1 = 178}$
 $\frac{1^{st} \text{ P.B.} \quad 2^{nd} \text{ P.B.}}$

* 1 (P) oocyte \longrightarrow 1 (S) oocyte \longrightarrow 1 Ovum
 $2n$ n n

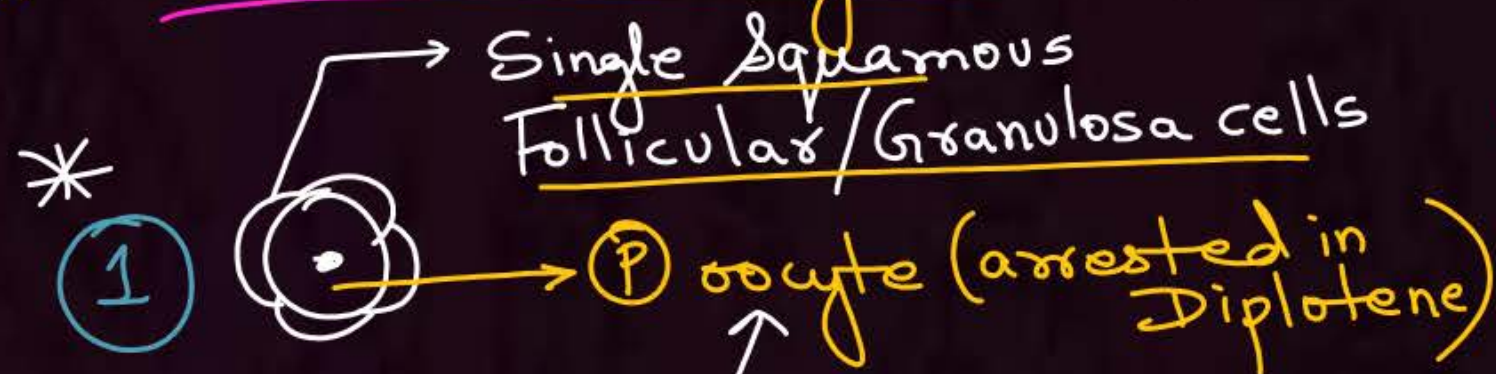


FOLLICLE DEVELOPMENT IN OVARY



* Couple of millions of oögonia formed before Birth
(7 million)

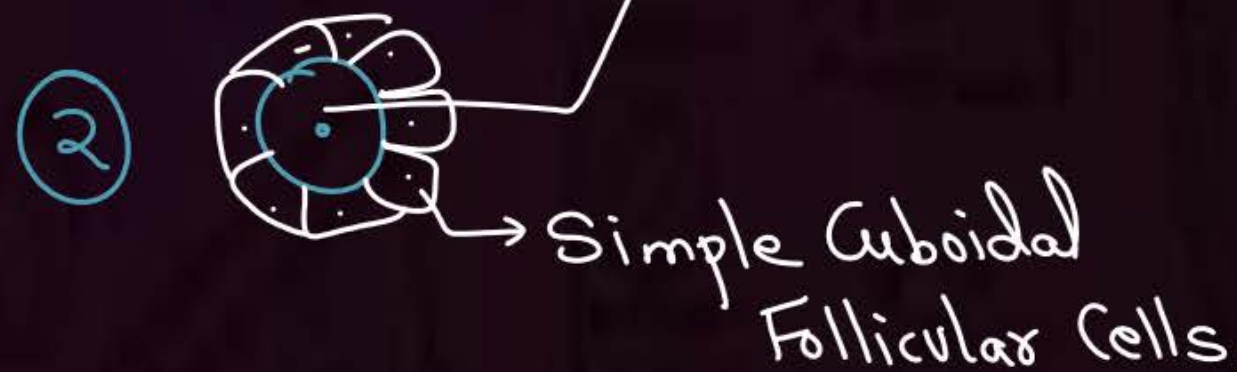
* No more Oögonia formed or added after Birth



Fact → **PRIMORDIAL FOLLICLE** (Not in NCERT)

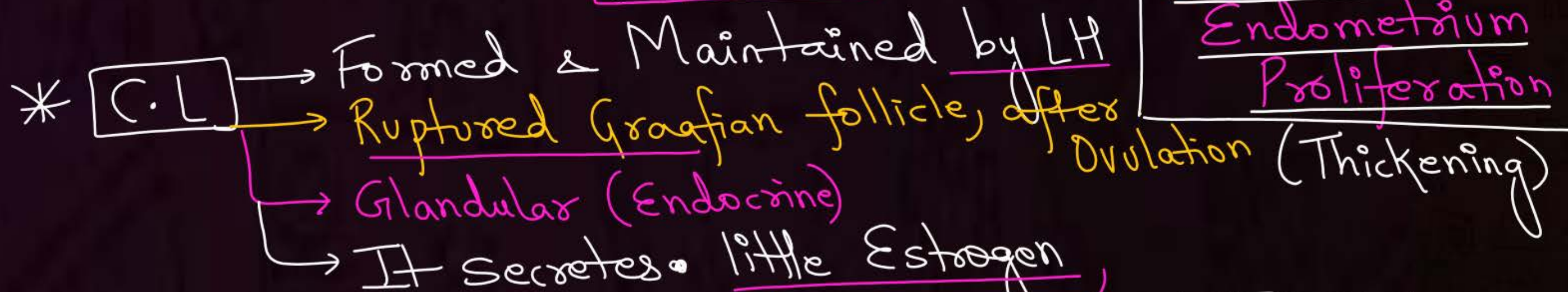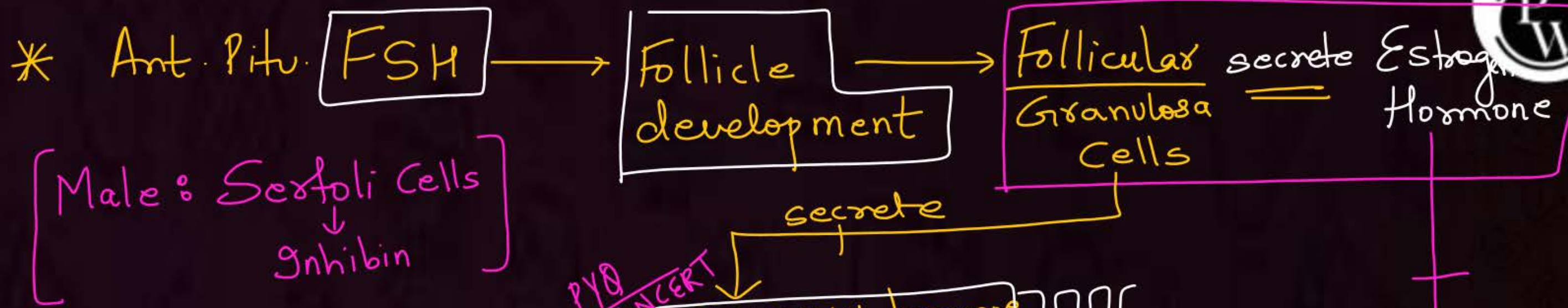
- At Birth 2 million / ovary (20 lac)
- At Puberty 2 lac / ovary

Follicular Atresia



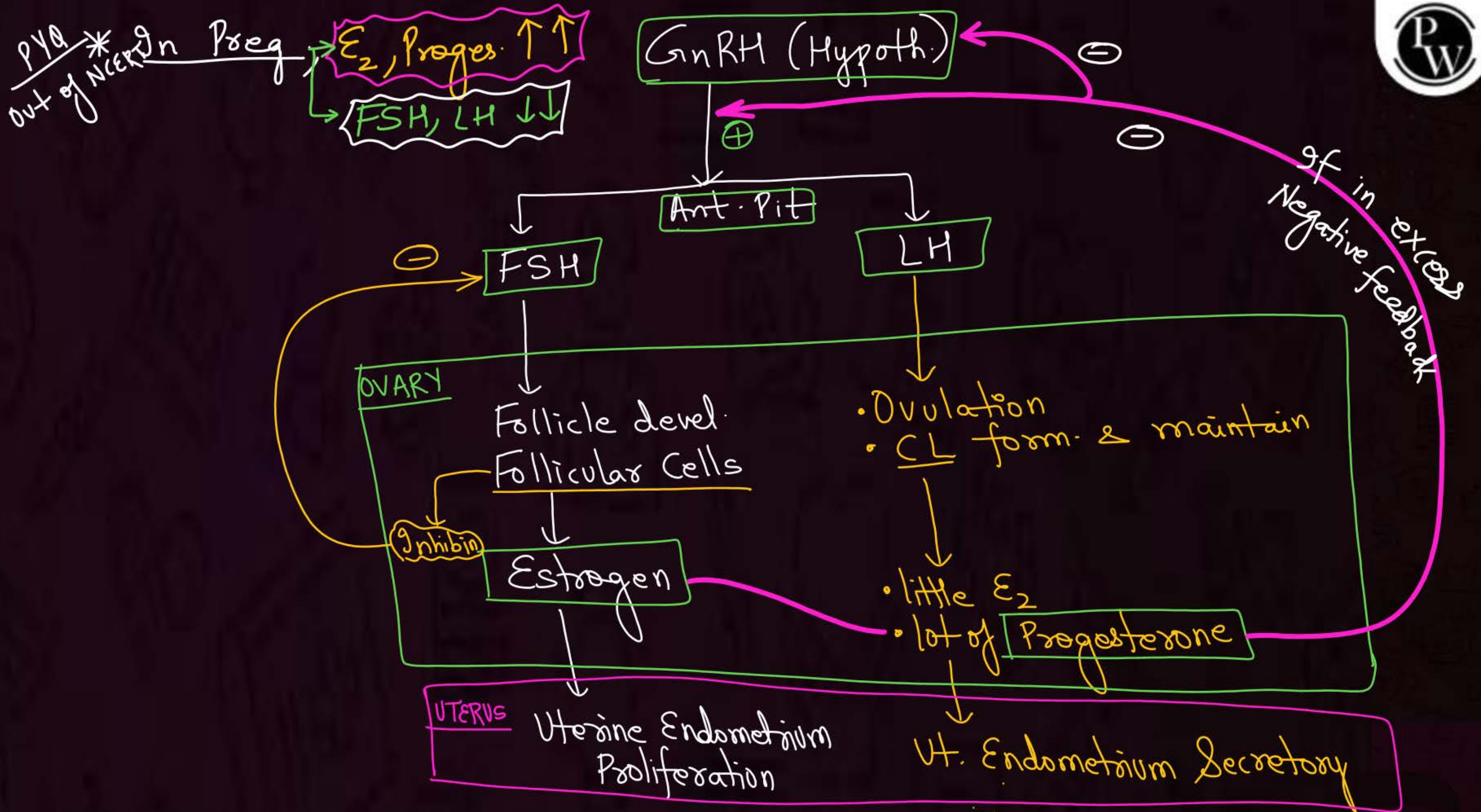
→ **PRIMARY FOLLICLE**

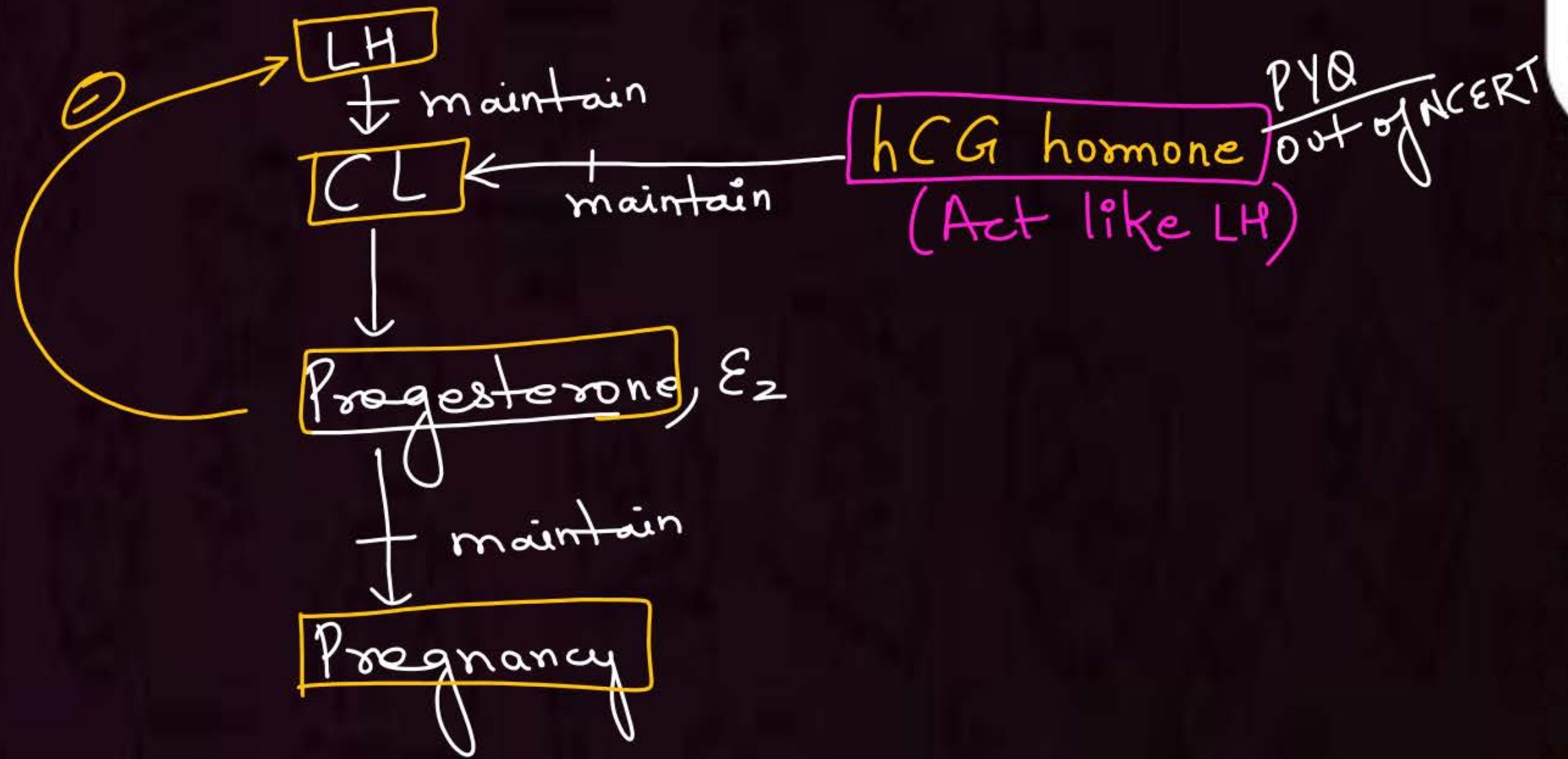
- At Puberty 60,000 - 80,000 / ovary
- NCERT :- At Birth



* Pregnancy Hormone
= Progesterone

- lot of Progesterone
 - Relaxin hormone (later part of Preg) → Ut. Endometrium Secretory
 - Inhibin "
-





2.3 GAMETOGENESIS

The primary sex organs – the testis in the males and the ovaries in the females – produce gametes, i.e., sperms and ovum, respectively, by the process called gametogenesis. In testis, the immature male germ cells (spermatogonia) produce sperms by **spermatogenesis** that begins at puberty. The **spermatogonia** (sing. spermatogonium) present on the inside wall of seminiferous tubules multiply by mitotic division and increase in numbers. Each spermatogonium is diploid and contains 46 chromosomes. Some of the spermatogonia called **primary spermatocytes** periodically undergo meiosis. A primary spermatocyte completes the first meiotic division (reduction division) leading to

formation of two equal, haploid cells called **secondary spermatocytes**, which have only 23 chromosomes each. The secondary spermatocytes undergo the second meiotic division to produce four equal, haploid **spermatids** (Figure 2.5). *What would be the number of chromosome in the spermatids?* The spermatids are transformed into **spermatozoa (sperms)** by the process called **spermiogenesis**. After spermiogenesis, sperm heads become embedded in the Sertoli cells, and are finally released from the seminiferous tubules by the process called **spermiation**. *into lumen of*

Spermatogenesis starts at the age of puberty due to significant increase in the secretion of gonadotropin releasing hormone

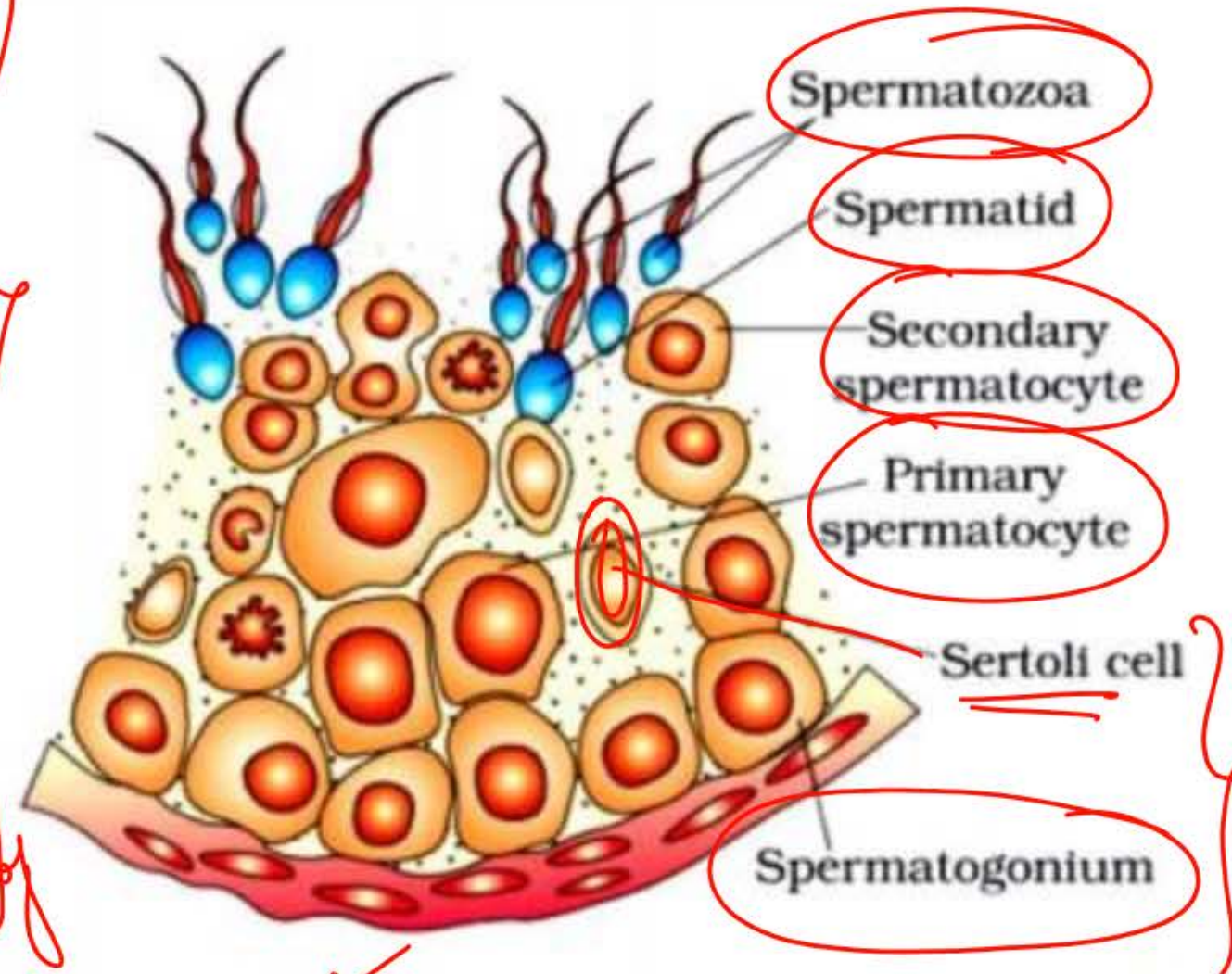


Figure 2.5 Diagrammatic sectional view of a seminiferous tubule (enlarged)

(GnRH). This, if you recall, is a hypothalamic hormone. The increased levels of GnRH then acts at the anterior pituitary gland and stimulates secretion of two gonadotropins – luteinising hormone (LH) and follicle stimulating hormone (FSH). LH acts at the Leydig cells and stimulates synthesis and secretion of androgens. Androgens, in turn, stimulate the process of spermatogenesis. FSH acts on the Sertoli cells and stimulates

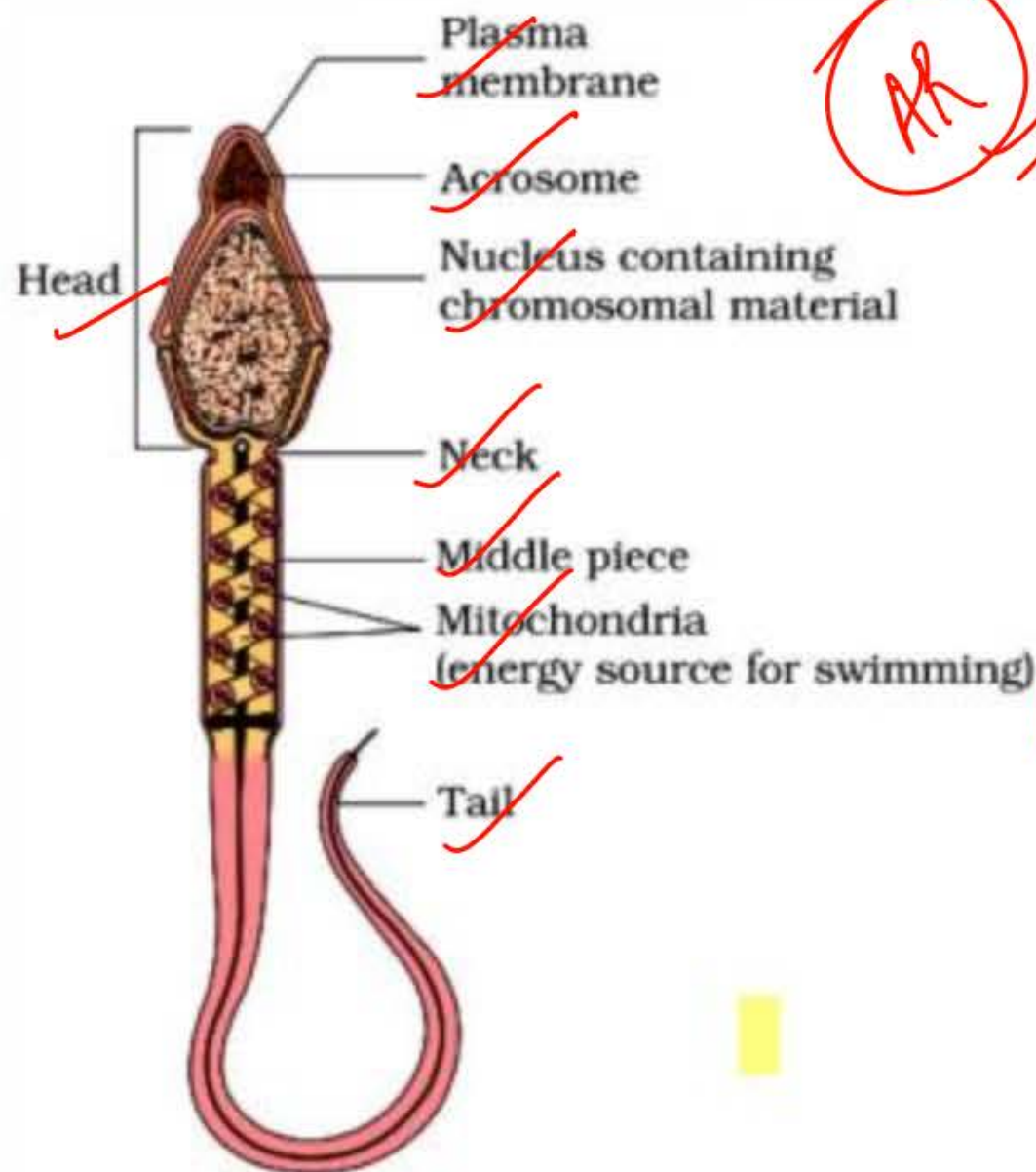


Figure 2.6 Structure of a sperm

secretion of some factors which help in the process of spermiogenesis.

Let us examine the structure of a sperm. It is a microscopic structure composed of a **head**, **neck**, a **middle piece** and a **tail** (Figure 2.6). A plasma membrane envelops the whole body of sperm. The sperm head contains an elongated haploid nucleus, the anterior portion of which is covered by a cap-like structure, **acrosome**. The acrosome is filled with enzymes that help fertilisation of the ovum. The middle piece possesses numerous mitochondria, which produce energy for the movement of tail that facilitate sperm motility essential for fertilisation.

The human male ejaculates about 200 to 300 million sperms during a coitus of which, for normal fertility, at least 60 per cent sperms must have normal shape and size and at least 40 per cent of them must show vigorous motility.

Sperms released from the seminiferous tubules, are transported by the accessory

ducts. Secretions of epididymis, vas deferens, seminal vesicle and prostate are essential for maturation and motility of sperms. The seminal plasma along with the sperms constitute the **semen**. The functions of male sex accessory ducts and glands are maintained by the testicular hormones (androgens).

The process of formation of a mature female gamete is called **oogenesis** which is markedly different from spermatogenesis. Oogenesis is initiated during the embryonic development stage when a couple of million gamete mother cells (**oogonia**) are formed within each fetal ovary; no more oogonia are formed and added after birth. These cells start division and enter into prophase-I of the meiotic division and get temporarily arrested at that stage, called **primary oocytes**. Each primary oocyte then gets surrounded by a layer of granulosa cells and is called the **primary follicle** (Figure 2.7). A

Question



A primary spermatocyte completes the first meiotic division leading to formation of

- ☒ **A** Two unequal, haploid cells called secondary spermatocytes
- ☒ **B** Four equal, haploid cells called secondary spermatocytes
- ☐ **C** Two equal, haploid cells called secondary spermatocytes
- ☒ **D** Two equal, diploid cells called secondary spermatocytes

————— **FOR NOTES & DPP CHECK DESCRIPTION** —————

Question

The secondary spermatocytes undergo the second meiotic division to produce

- A** ~~Four equal, haploid spermatids~~
- B** ~~Four unequal, haploid spermatozoa~~
- C** ~~Four unequal, haploid spermatids~~
- D** ~~Four equal, haploid spermatozoa~~

———— **FOR NOTES & DPP CHECK DESCRIPTION** ————

Question

Which of the following group represents diploid cells?

- A** Primary Spermatocytes, Secondary ~~spermatocytes~~ ⁿ
- B** Spermatogonia, ~~Spermatozoa~~ ²ⁿ ⁿ
- C** Secondary ~~spermatocytes~~ ⁿ, ~~Spermatozoa~~ ⁿ
- D** Primary Spermatocytes, Spermatogonia

———— FOR NOTES & DPP CHECK DESCRIPTION ————

100 Spermatogonia give rise to

- A** 100 primary spermatocytes, ~~400~~ secondary spermatocytes, 600 spermatids, 400 spermatozoa
- B** 100 primary spermatocytes, ~~400~~ secondary spermatocytes, 800 spermatids, 800 spermatozoa
- C** ~~100~~ primary spermatocytes, 200 secondary spermatocytes, 400 spermatids, 400 spermatozoa
- D** 100 primary spermatocytes, 200 secondary spermatocytes, 400 spermatids, ~~800~~ spermatozoa

Question



Find out the correct statement with respect to human sperm

- A** The neck is filled with enzymes that help in fertilisation of the ovum


X Acros. (head)
- B** The head of sperm contains a diploid nucleus

Xⁿ
- C** The middle piece possesses numerous mitochondria, which produce energy for the movement of sperm

✓
- D** Sperm shows ciliary movement

X flagella

————— **FOR NOTES & DPP CHECK DESCRIPTION** —————

- **1 primary oocyte – one secondary oocyte and 1 polar body**
 - **one secondary oocyte – one ovum + one polar body**
 - **1 oogonia – one ovum & 2-3 polar body**
 - **One primary oocyte – one ovum + 2 - 3 polar body**
 - **1st polar body – degenerates in human & most vertebrates**
- 

———— **FOR NOTES & DPP CHECK DESCRIPTION** ————

large number of these follicles degenerate during the phase from birth to puberty. Therefore, at puberty only 60,000-80,000 primary follicles are left in each ovary. The primary follicles get surrounded by more layers of granulosa cells and a new theca and are called **secondary follicles**.

The secondary follicle soon transforms into a tertiary follicle which is characterised by a fluid filled cavity called **antrum**. The theca layer is organised into an inner theca interna and an outer theca externa. It is important to draw your attention that it is at this stage that the primary oocyte within the tertiary follicle grows in size and completes its first meiotic division. It is an unequal division resulting in the formation of a large haploid **secondary oocyte** and a tiny first polar body (Figure 2.8b). The

secondary oocyte retains bulk of the nutrient rich cytoplasm of the primary oocyte. Can you think of any advantage for this? Does the first polar body born out of first meiotic division divide further or degenerate? At present we are not very certain about this. The tertiary follicle further changes into the mature follicle or **Graafian follicle** (Figure 2.7). The secondary oocyte forms a new membrane called **zona pellucida** surrounding it. The Graafian follicle now ruptures to release the secondary oocyte (ovum) from the ovary by the process called **ovulation**. Can you identify major differences between spermatogenesis and oogenesis? A diagrammatic representation of spermatogenesis and oogenesis is given below (Figure 2.8).

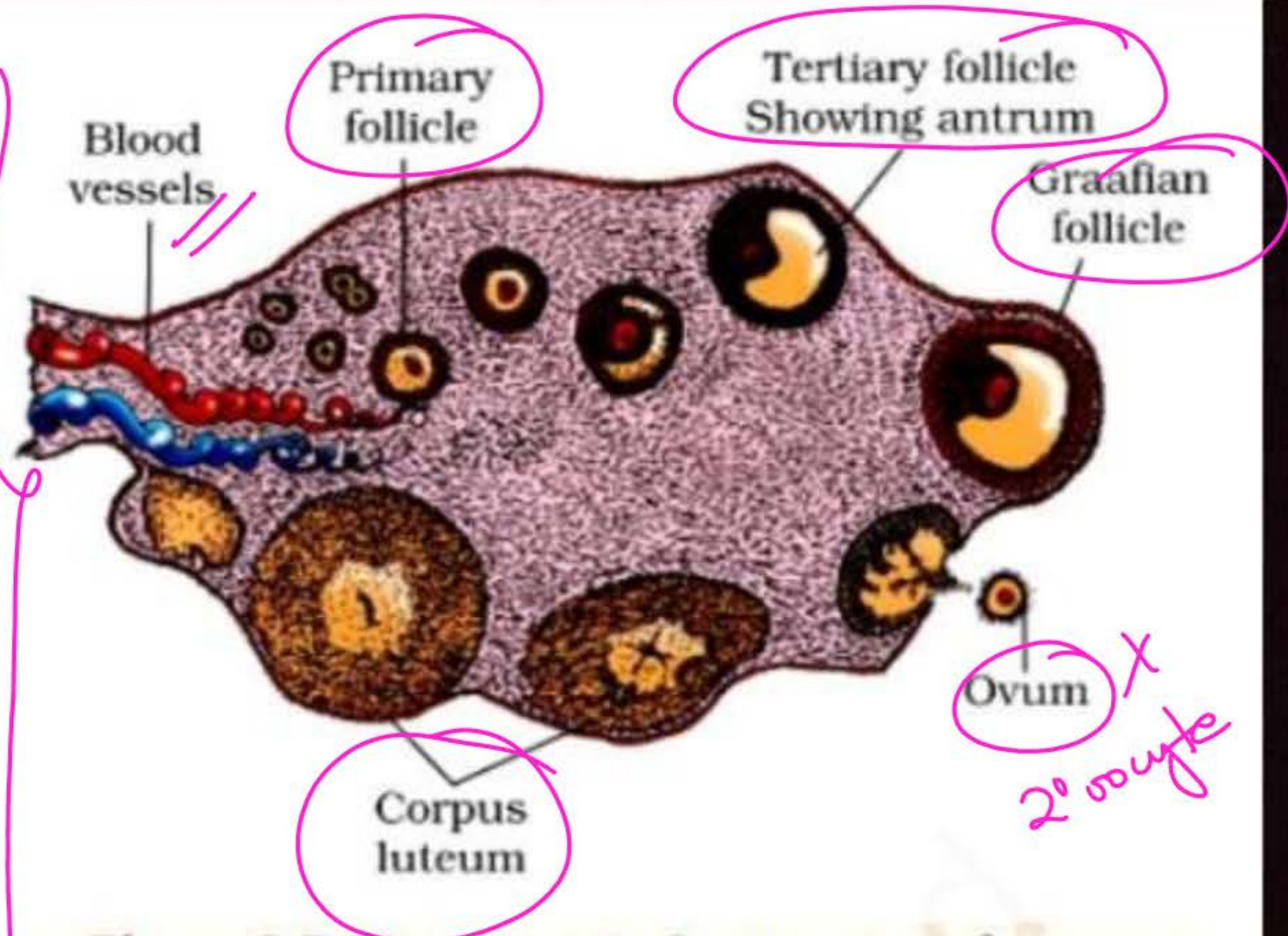


Figure 2.7 Diagrammatic Section view of ovary

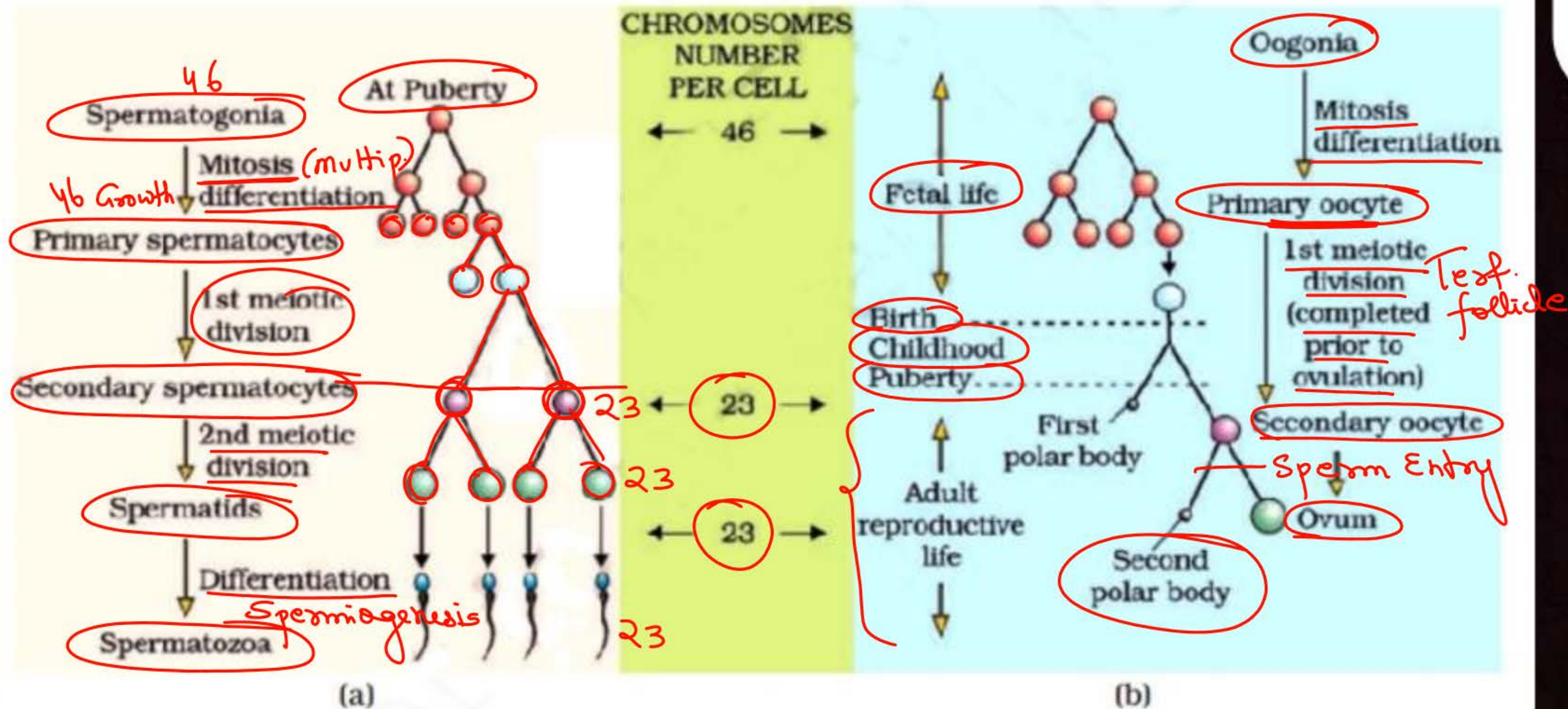


Figure 2.8 Schematic representation of (a) Spermatogenesis; (b) Oogenesis

SPERMATOGENESIS

1. Formation of Male Gamete
2. Starts At PUBERTY
3. Starts & Ends in Testis
4. Continues even in Old Age

5. $1 \overset{2n}{\text{Primary Spermatoocyte}} \xrightarrow{\text{Equal division}} 2 \overset{\text{haploid}}{\text{Equal Spermatoocyte}} \text{ (S)}$

6. $2 \text{ (S)} \xrightarrow{\text{Equal division}} 4 \text{ Equal Spermatoids (n)}$

7. Spermatoid $\xrightarrow{\text{Transformation}} \text{Spermatozoa (n)}$
SPERMIOGENESIS

8. Occurs Continuously

OÖGENESIS

- Formation of Female gamete
- Starts in Embryonic life
- Starts in fetal Ovary but Ends in Fallopian tube
- Stops at Menopause (No More Oogonia formed & added after birth)

• $1 \text{ (P) oocyte (2n)} \xrightarrow{\text{Unequal}} 1 \overset{\text{larger}}{\text{(S) oocyte}} + 1 \overset{\text{1st P.B}}{\text{tiny (n)}}$

• $1 \text{ (S) oocyte (n)} \xrightarrow{\text{Unequal}} 1 \text{ Ovum (large (n))} + 1 \overset{\text{2nd P.B}}{\text{tiny (n)}}$

• No Such differentiation occurs

• Occurs discontinuously [Prophase-I, Metaph-II]

SPERMATOGENESIS

9. Spermatozoa MOTILE
(Gamete)

10. Spermatozoa: Very little
Cytoplasm

OÖGENESIS

• Ovum → Non-motile
(♀ Gamete)

• Ovum → Bulk Cytoplasm

Question



H.W

Match the following Lists:

- A** a – iii, b – iv, c – i, d – ii
- B** a – iv, b – iii, c – i, d – ii
- C** a – ii, b – iv, c – i, d – iii
- D** a – i, b – iv, c – iii, d – ii

| List-I | | List-II | |
|--------|--------------------|---------|---|
| a. | Primary Follicle | (i) | 60,000-80,000 left in each ovary at the time of puberty |
| b. | Secondary Follicle | (ii) | Mature follicle that ruptures at the time of ovulation |
| c. | Tertiary Follicle | (iii) | Primary oocyte completes meiosis-I |
| d. | Graafian Follicle | (iv) | More layers of granulosa cells and a theca layer |

————— **FOR NOTES & DPP CHECK DESCRIPTION** —————

Question

Find the correct sequence of events in oogenesis if fertilisation occurs.

- A** Oogonia → primary oocyte → secondary oocyte → ovum
- B** Oogonia → secondary oocyte → primary oocyte → ovum
- C** Oogonia → primary oocyte → ovum → secondary polar body
- D** Oogonia → first polar body → secondary oocyte → ovum

————— **FOR NOTES & DPP CHECK DESCRIPTION** —————

Question

Find the odd one out with respect to ploidy of the cells

- A** Primary Oocyte
- B** Ovum
- C** Secondary oocyte
- D** Second polar body

———— **FOR NOTES & DPP CHECK DESCRIPTION** ————

Question



Identify A, B, C, D correctly

A

A – Graafian follicle
B – Secondary follicle
C – Corpus albicans
D – Primary oocyte

B

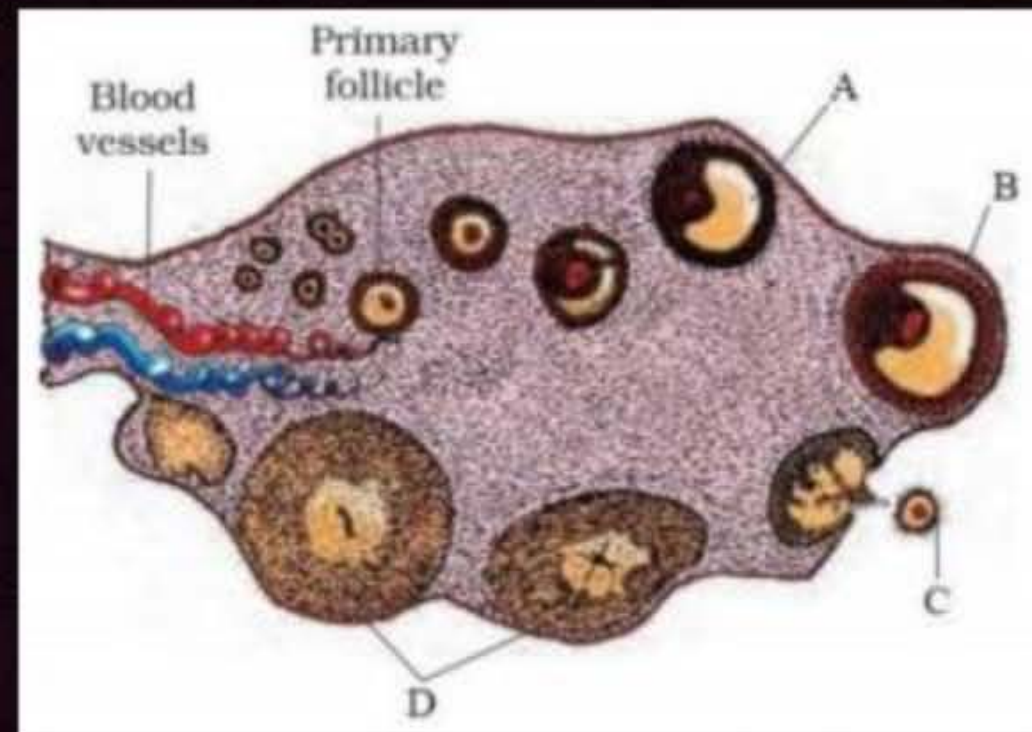
A – Tertiary follicle
B – Graafian follicle
C – Corpus luteum
D – Ovum

C

A – Tertiary follicle
B – Graafian follicle
C – Ovum
D – Corpus luteum

D

A – Tertiary follicle
B – Corpus luteum
C – Secondary oocyte
D – Corpus albicans



————— **FOR NOTES & DPP CHECK DESCRIPTION** —————

Question

If fertilisation occurs, secondary oocyte completes Meiosis II to form

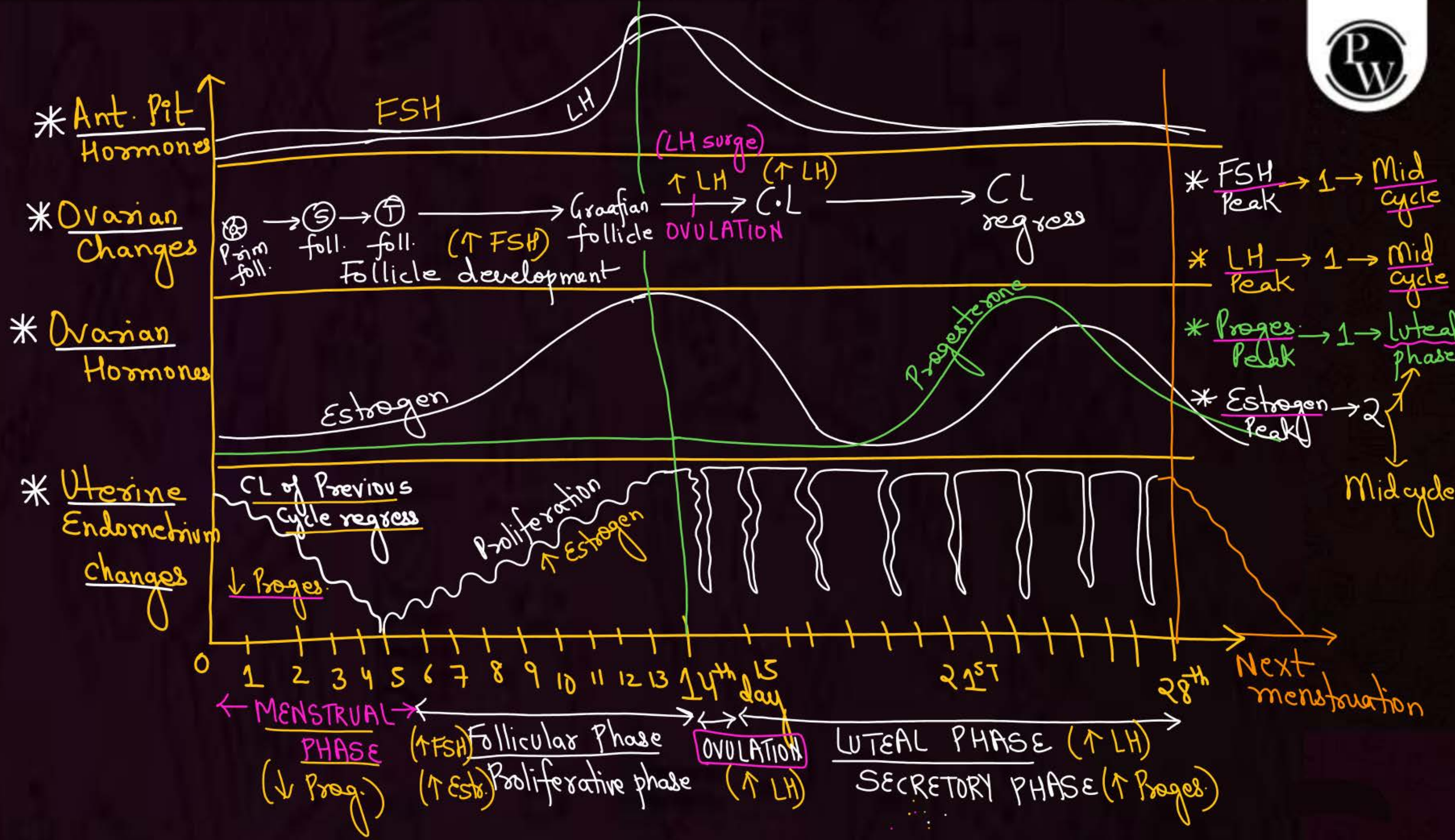
- A** Two haploid, equal cells – second polar body, ovum
- B** Two haploid, unequal cells – second polar body, ovum
- C** Two haploid, unequal cells – first polar body, second polar body
- D** Two diploid, unequal cells – second polar body, ovum

———— **FOR NOTES & DPP CHECK DESCRIPTION** ————

2.4 MENSTRUAL CYCLE

*Estrous Cycle :- Non-Primate mammals
eg. Dog, Cats, Cow*

The reproductive cycle in the female primates (e.g. monkeys, apes and human beings) is called menstrual cycle. The first menstruation begins at puberty and is called **menarche**. In human females, menstruation is repeated at an average interval of about 28/29 days, and the cycle of events starting from one menstruation till the next one is called the **menstrual cycle**. One ovum is released (ovulation) during the middle



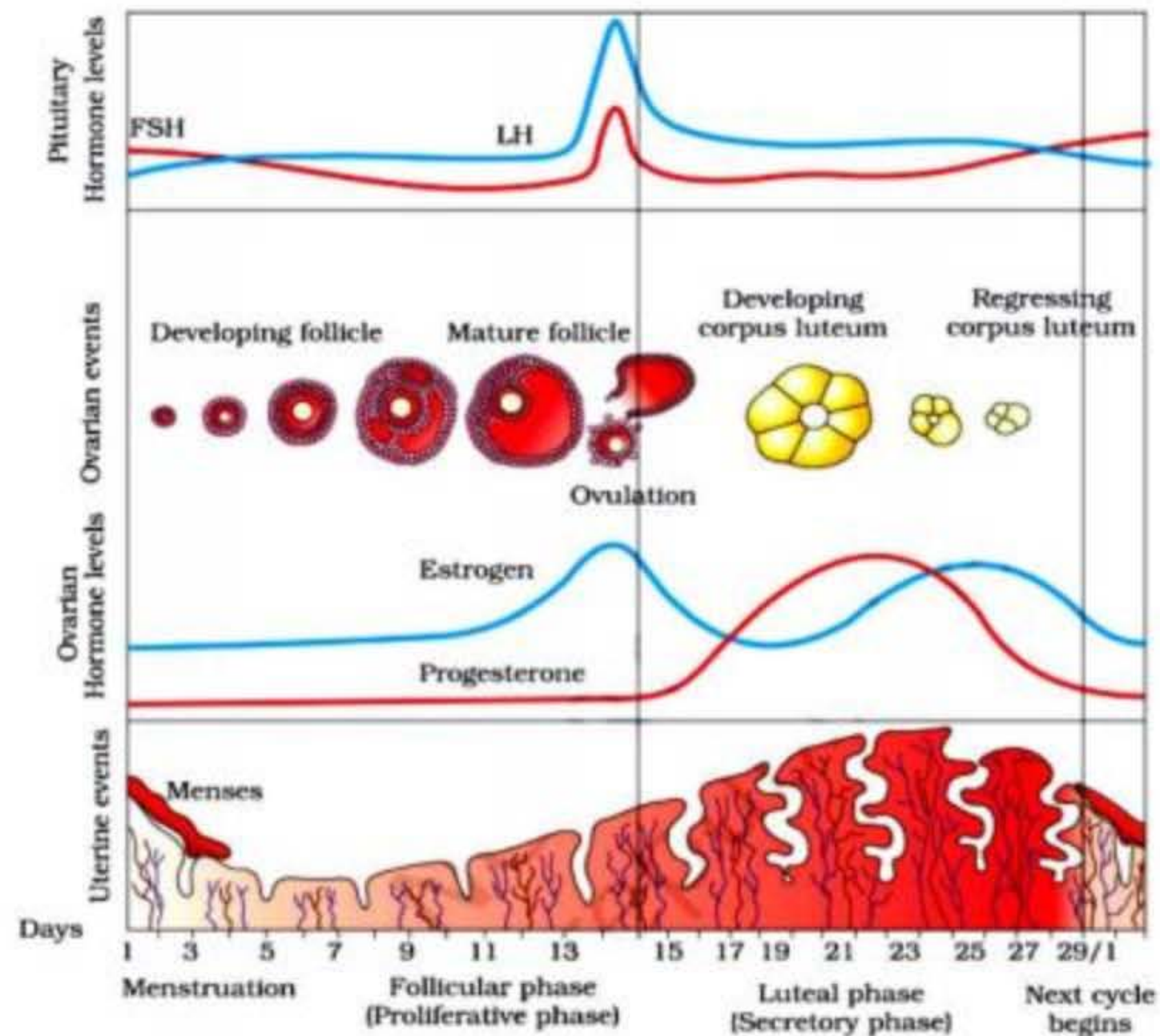


Figure 2.9 Diagrammatic presentation of various events during a menstrual cycle

———— **FOR NOTES & DPP CHECK DESCRIPTION** ————

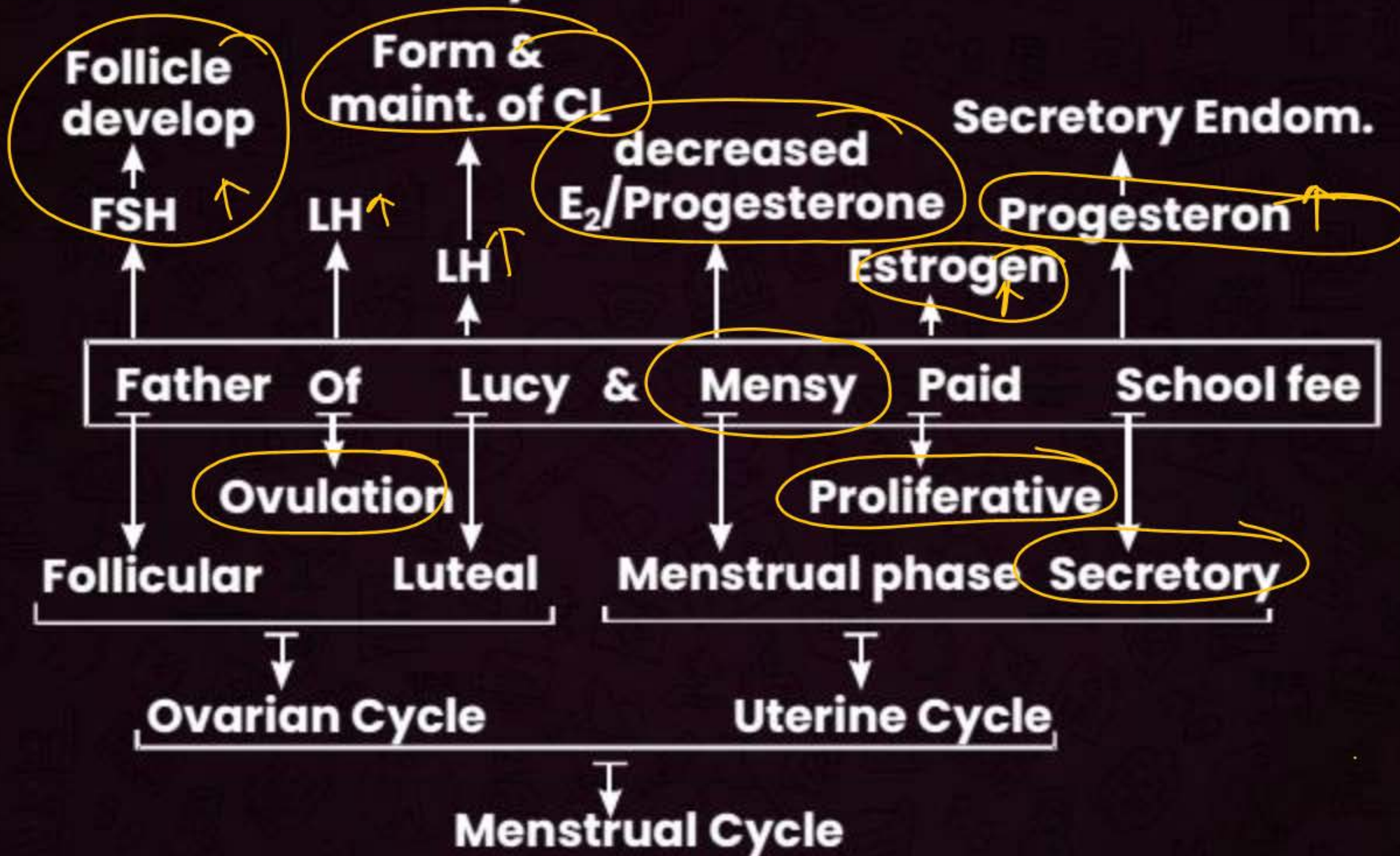
of each menstrual cycle. The major events of the menstrual cycle are shown in Figure 2.9. The cycle starts with the menstrual phase, when menstrual flow occurs and it lasts for 3-5 days. The menstrual flow results due to breakdown of endometrial lining of the uterus and its blood vessels which forms liquid that comes out through vagina. Menstruation only occurs if the released ovum is not fertilised. Lack of menstruation may be indicative of pregnancy. However, it may also be caused due to some other underlying causes like stress, poor health etc. The menstrual phase is followed by the follicular phase. During this phase, the primary follicles in the ovary grow to become a fully mature Graafian follicle and simultaneously the endometrium of uterus regenerates through proliferation. These changes in the ovary and the uterus are induced by changes in the levels of pituitary and ovarian hormones (Figure 2.9). The secretion of

gonadotropins (LH and FSH) increases gradually during the follicular phase, and stimulates follicular development as well as secretion of estrogens by the growing follicles. Both LH and FSH attain a peak level in the middle of cycle (about 14th day). Rapid secretion of LH leading to its maximum level during the mid-cycle called LH surge induces rupture of Graafian follicle and thereby the release of ovum (ovulation). The ovulation (ovulatory phase) is followed by the luteal phase during which the remaining parts of the Graafian follicle transform as the **corpus luteum** (Figure 2.9). The corpus luteum secretes large amounts of progesterone which is essential for maintenance of the endometrium. Such an endometrium is necessary for implantation of the fertilised ovum and other events of pregnancy. During pregnancy all events of the menstrual cycle stop and there is no menstruation. In the absence of fertilisation, the corpus luteum degenerates. This causes disintegration of the endometrium leading to menstruation, marking a new cycle. In human beings, menstrual cycles ceases around 50 years of age; that is termed as **menopause**. Cyclic menstruation is an indicator of normal reproductive phase and extends between menarche and menopause.

Menstrual Hygiene

Maintenance of hygiene and sanitation during menstruation is very important. Take bath and clean yourself regularly. Use sanitary napkins or clean homemade pads. Change sanitary napkins or homemade pads after every 4-5 hrs as per the requirement. Dispose of the used sanitary napkins properly wrapping it with a used paper. Do not throw the used napkins in the drainpipe of toilets or in the open area. After handling the napkin wash hands with soap.

Trick for Menstrual Cycle



———— **FOR NOTES & DPP CHECK DESCRIPTION** ————

Question



Match the following

- A** ~~a - iii, b - iv, c - i, d - ii~~
- B** ~~a - iv, b - iii, c - i, d - ii~~
- C** ~~a - ii, b - iv, c - i, d - iii~~
- D** ~~a - i, b - iv, c - iii, d - ii~~

| | | | |
|----|------------------|-------|--|
| a. | Menstrual Phase | (i) | Graafian follicle ruptures to release the ovum |
| b. | Follicular phase | (ii) | Corpus luteum secretes progesterone and estrogen |
| c. | Ovulation | (iii) | Follicular development and endometrium repair |
| d. | Luteal phase | (iv) | Endometrium breakdown and released from uterus |

————— FOR NOTES & DPP CHECK DESCRIPTION —————

Question



Find the incorrect statement about menstruation.

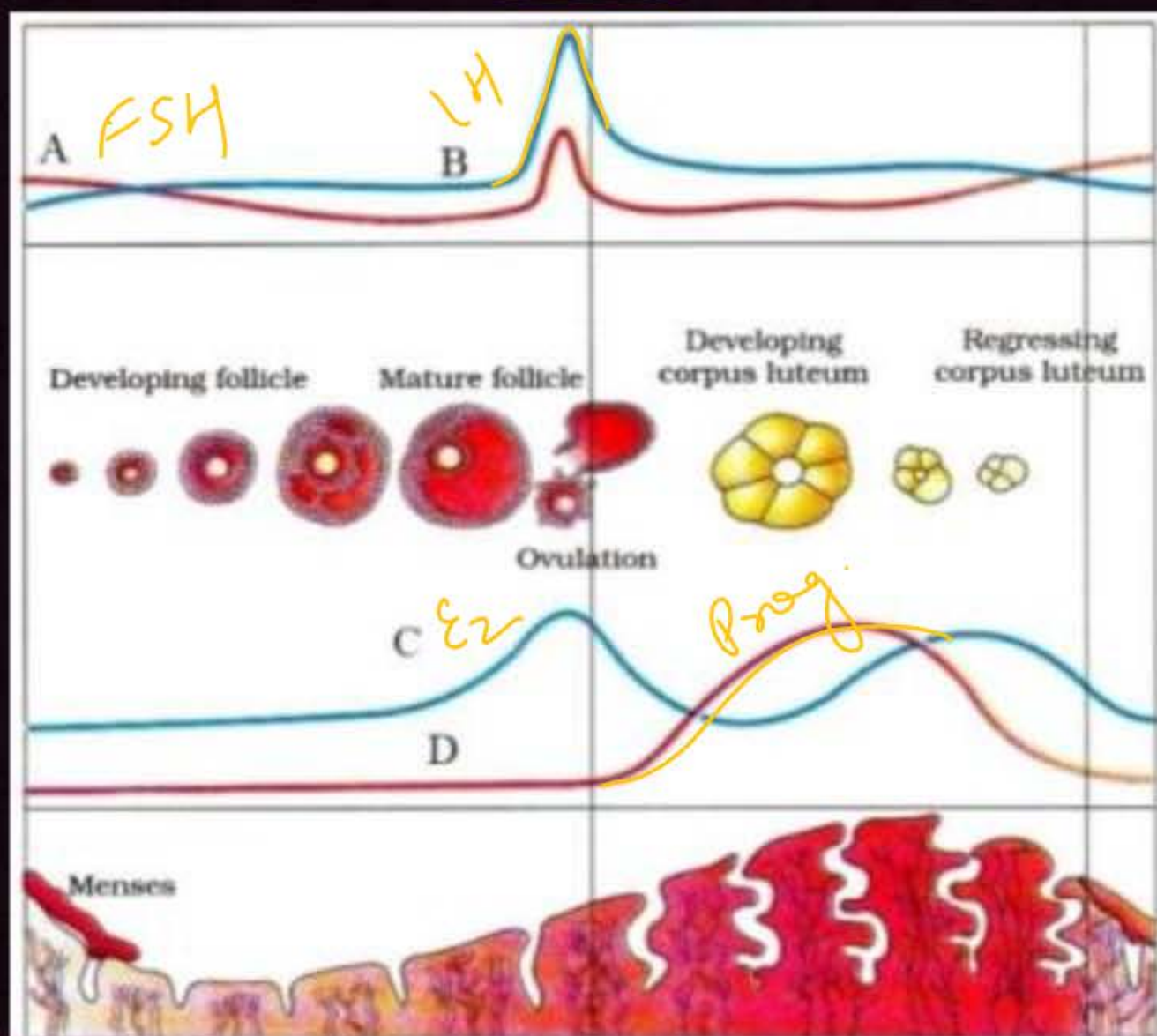
False

- A** The menstrual flow results due to breakdown of endometrial lining of the uterus. ✓
- B** Breakdown of endometrial lining of the uterus and its blood vessels which forms liquid that comes out through vagina. ✓
- C** Menstruation occurs if the released ovum is not fertilized. ✓
- D** Lack of menstruation occurs only because of pregnancy. ✗

————— **FOR NOTES & DPP CHECK DESCRIPTION** —————

Question

Hormone which stimulates follicular development is



A

A

B

B

C

C

D

D

FOR NOTES & DPP CHECK DESCRIPTION

Question



Select the incorrect statement about female hormonal activity

False

- A** The secretion of LH and FSH increases gradually during the follicular phase ✓
- B** LH surge induces rupture of graafian follicle and thereby ovulation ✓
- C** The corpus luteum secretes large amounts of progesterone ✓
- D** Inhibin gives positive feedback to FSH ~~ve~~

————— **FOR NOTES & DPP CHECK DESCRIPTION** —————



Immunity Booster
= Short notes

Insemination

Release of Semen by penis into Vagina during copulation



Motile Sperms swim rapidly, pass through Cervix, Enter into Uterus and reach Ampullary region of FT

^{2° oocyte}
Ovum released by Ovary also reaches ampulla (Site of fert.)

A Sperm comes in contact with ZP layer of Ovum & induces changes in membrane that block entry of additional Sperms

Ensures Only 1 Sperm fertilise Ovum

Secretions of Acrosome helps Sperm enter into Cytoplasm of Ovum through ZP & Plasma membrane.

Induces Completion of M-II of 2° oocyte (Unequal) \rightarrow 2nd P.B (n)
Ovum/Ootid (n)

haploid nucleus of Sperm fuses with that of Ovum to form Zygote (2n)



SWAYAMBAR

... Pyar Ka Bandhan ...

Trick for Steps in Fertilization



Celina
And



Company went to

Zyed
Mallika's
Shaadi

→

→

→

→

→

→

Capacitation of sperms (Ca²⁺)

AF-F reaction &

Acroosome reaction (Ca²⁺)

*Fast block to polyspermy (Na⁺)

Cortical reaction (Ca²⁺)

*Slow block to polyspermy (Ca⁺)

Zona reaction

Meiosis-II Completion

Syngamy

H.W



* Out of NCERT PYQ Capacitation

- Physiological maturation of Sperms
- In Female Reproductive Tract
- takes 6-7 hrs.

2.5 FERTILISATION AND IMPLANTATION

During copulation (coitus) semen is released by the penis into the vagina (insemination). The motile sperms swim rapidly, pass through the cervix, enter into the uterus and finally reach the ampullary region of the fallopian tube (Figure 2.11b). The ovum released by the ovary is also

transported to the ampullary region where fertilisation takes place.

Fertilisation can only occur if the ovum and sperms are transported simultaneously to the ampullary region. This is the reason why not all copulations lead to fertilisation and pregnancy.

The process of fusion of a sperm with an ovum is called **fertilisation**. During fertilisation, a sperm comes in contact with the zona pellucida layer of the ovum (Figure 2.10) and induces changes in the membrane that block the entry of additional sperms. Thus, it ensures that only one sperm can fertilise an ovum. The secretions of the acrosome help the sperm enter into the cytoplasm of the ovum through the zona pellucida and the plasma

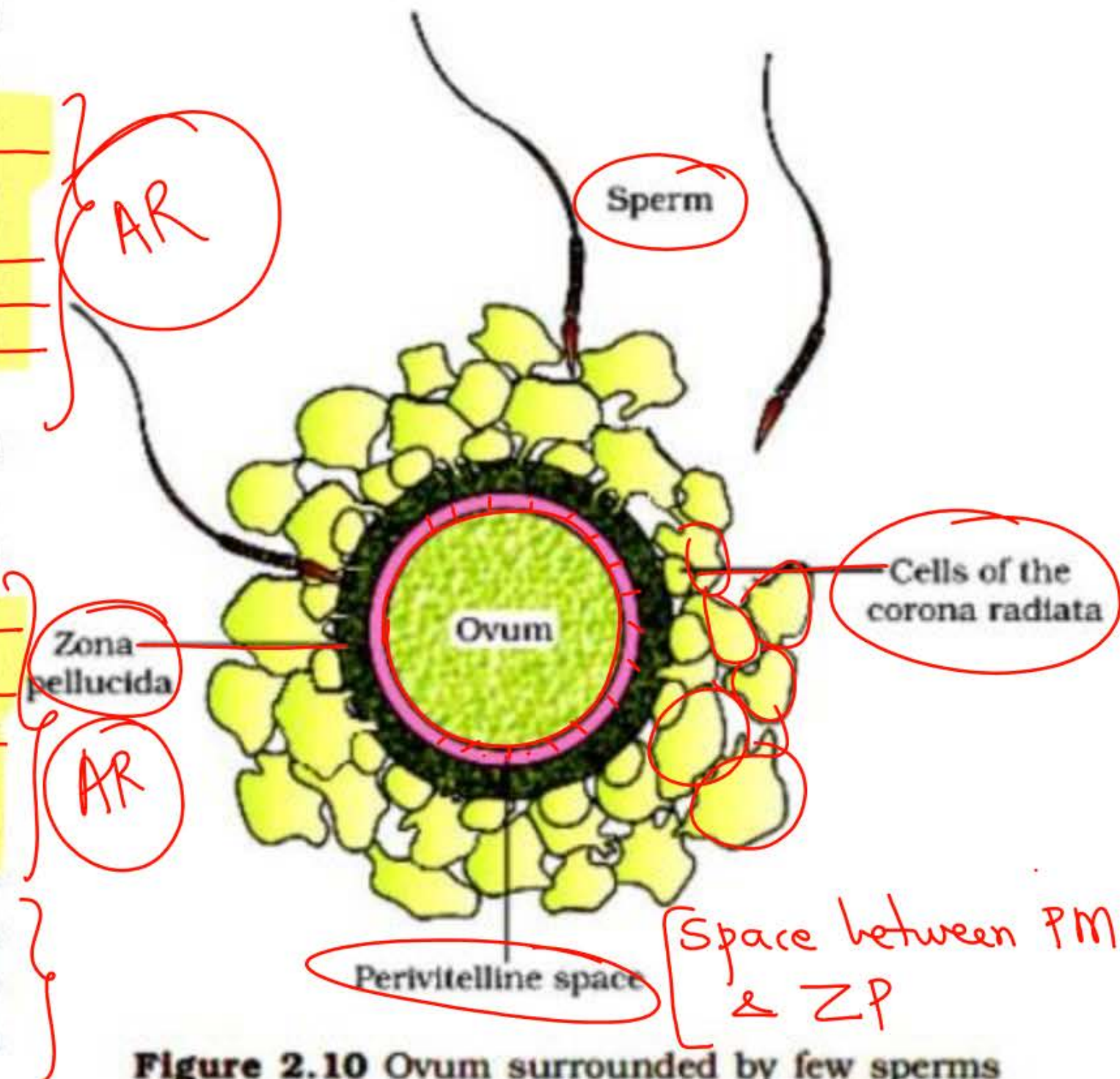
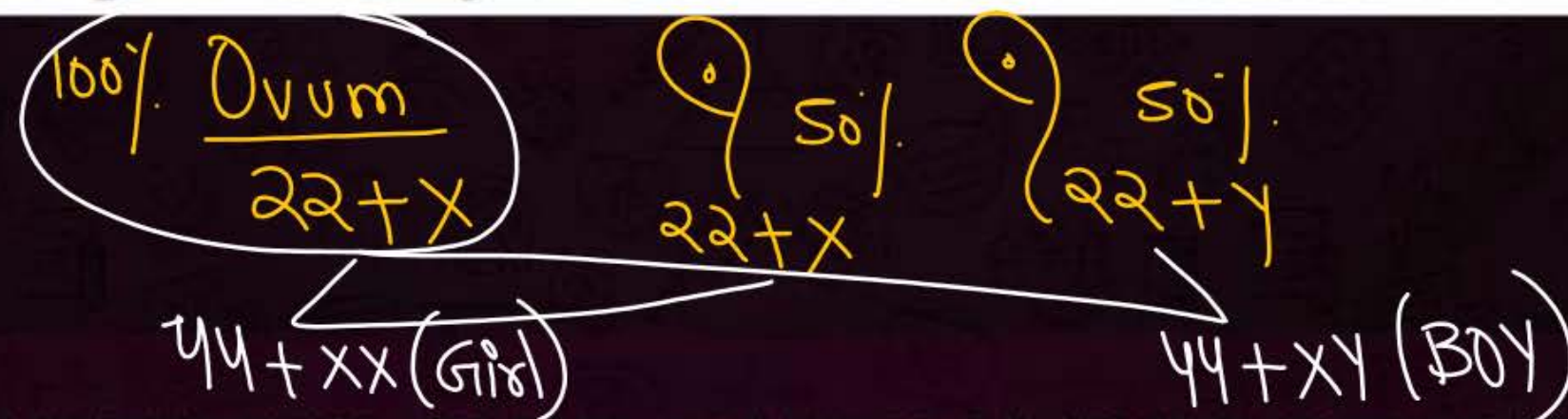


Figure 2.10 Ovum surrounded by few sperms

membrane. This induces the completion of the meiotic division of the secondary oocyte. The second meiotic division is also unequal and results in the formation of a **second polar body** and a haploid ovum (ootid). Soon the haploid nucleus of the sperms and that of the ovum fuse together to form a diploid **zygote**. *How many chromosomes will be there in the zygote?*

One has to remember that the sex of the baby has been decided at this stage itself. *fertilisation* Let us see how? As you know the chromosome pattern in the human female is XX and that in the male is XY. Therefore, all the haploid gametes (ova) produced by the female have the sex chromosome X whereas in the male gametes (sperms) the sex chromosome could be either X or Y, hence, 50 per cent of sperms carry the X chromosome while the other 50 per



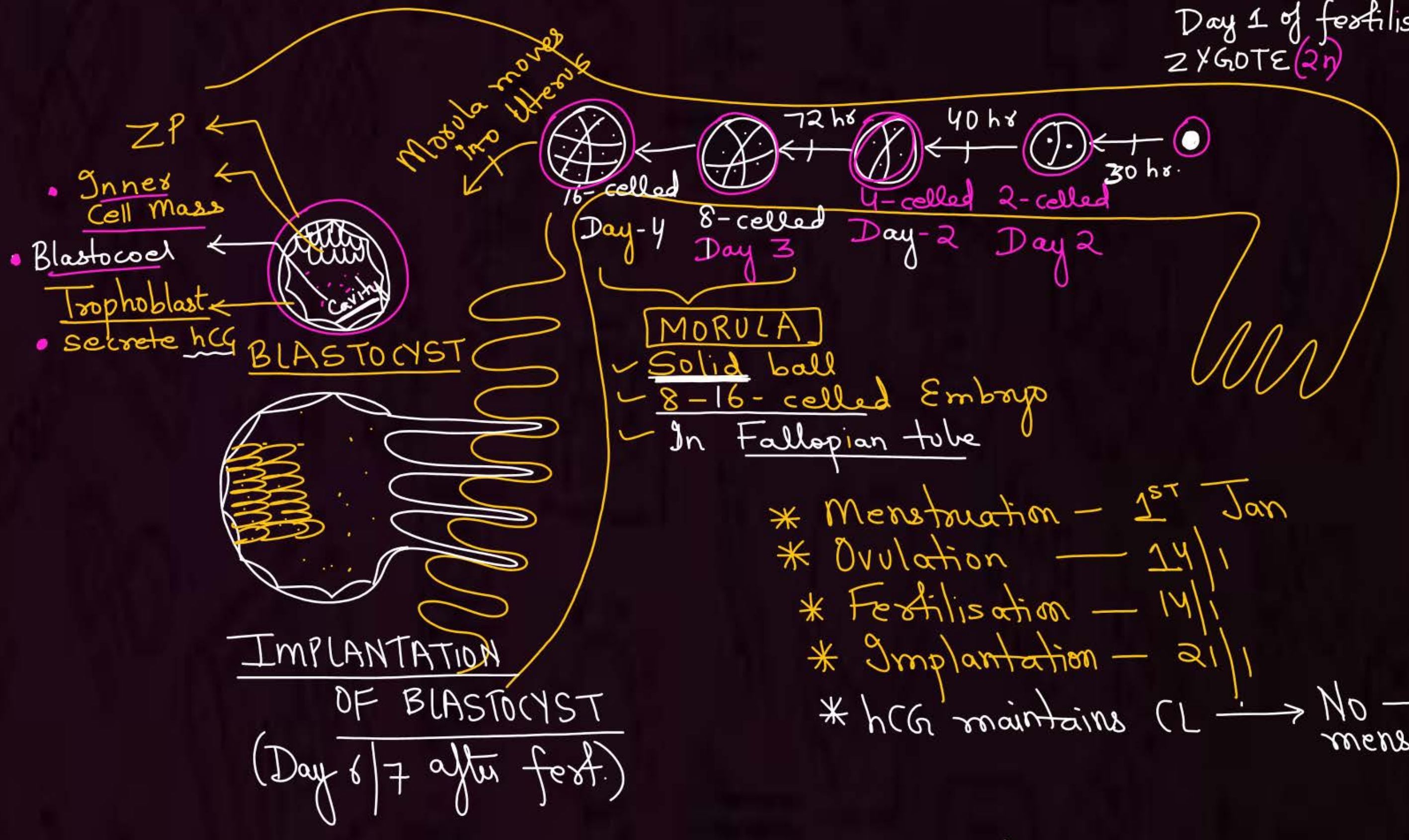
FOR NOTES & DPP CHECK DESCRIPTION

cent carry the Y. After fusion of the male and female gametes the zygote would carry either XX or XY depending on whether the sperm carrying X or Y fertilised the ovum. The zygote carrying XX would develop into a female baby and XY would form a male (you will learn more about the chromosomal patterns in Chapter 5). That is why, scientifically it is correct to say that the sex of the baby is determined by the father and not by the mother! AR

The mitotic division starts as the zygote moves through the isthmus of the oviduct called **cleavage** towards the uterus (Figure 2.11) and forms 2, 4, 8, 16 daughter cells called **blastomeres**. The embryo with 8 to 16



Day 1 of fertilisation
2XGOTE (2n)



- MORULA**
- ✓ Solid ball
 - ✓ 8-16-celled Embryo
 - ✓ In Fallopian tube

- * Menstruation — 1st Jan
- * Ovulation — 14/1
- * Fertilisation — 14/1
- * Implantation — 21/1
- * hCG maintains CL

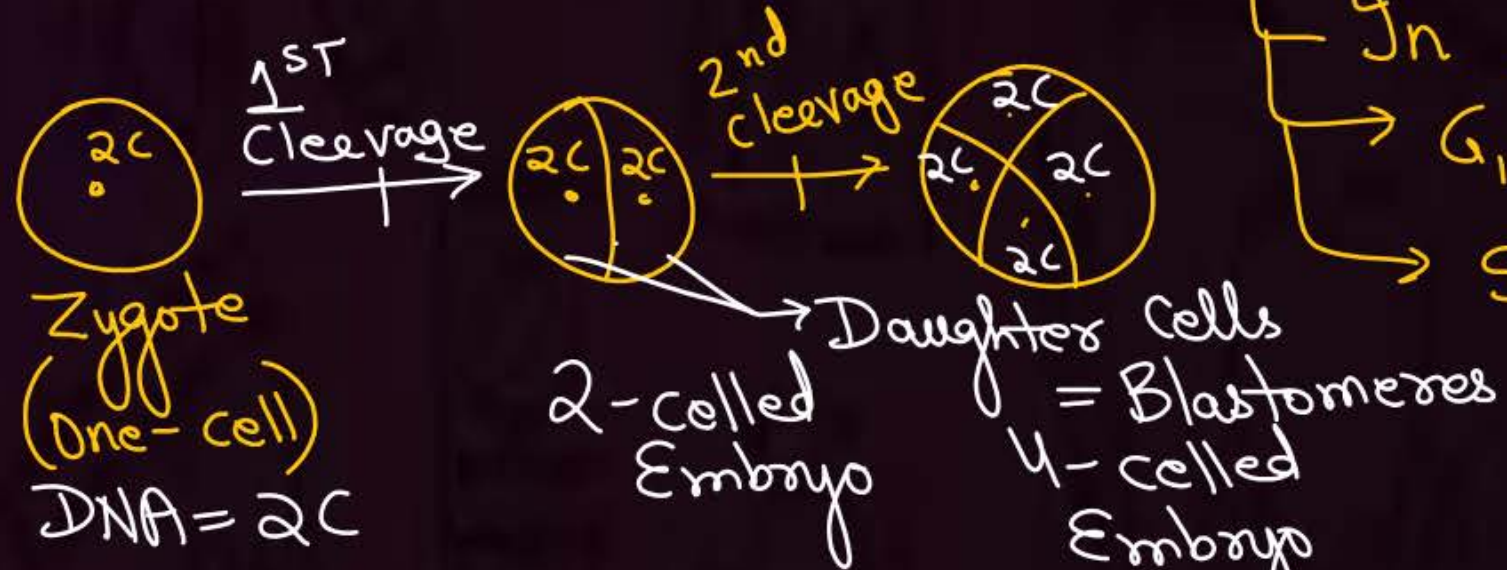
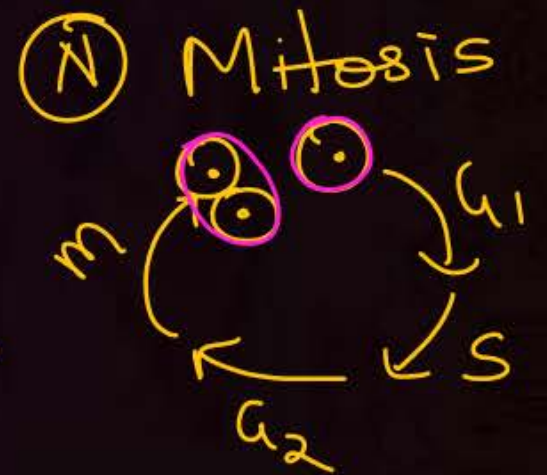No menses on 30/1 → Check UPT+ve [hCG]



PYQ
Out of
NCERT

ECTOPIC preg :- Implantation, at other than normal site
due to pre-mature rupture of ZP

* CLEAVAGE DIVISIONS :- special type of Mitotic division
In Fallopian tube
G₁ / G₂ negligible
absent
S-present



* Total Volume of Zygote = Total Vol. of 2/4/8/16-celled Embryo
* Size of blastomeres ↓ ing
* DNA Content ↑ ing

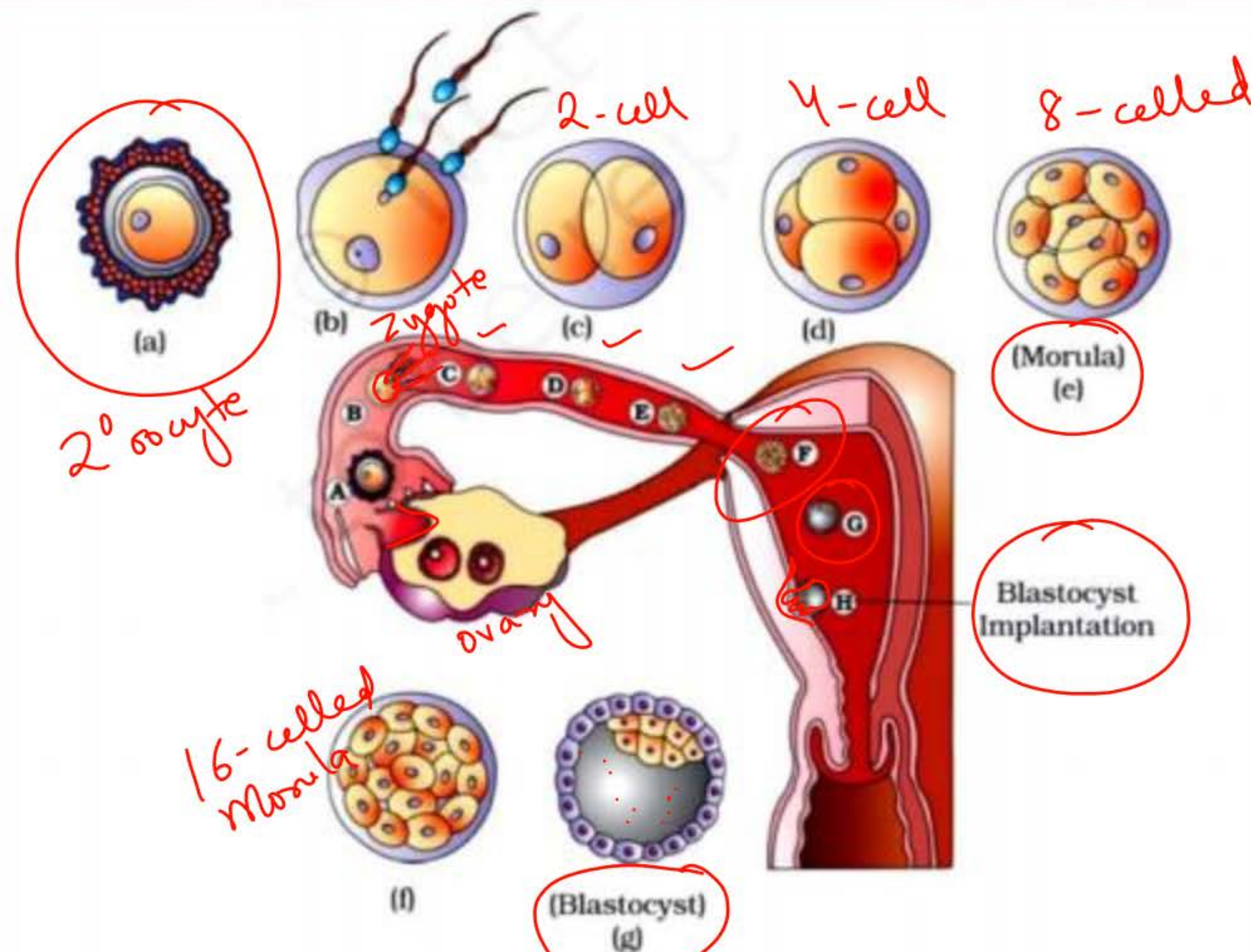


Figure 2.11 Transport of ovum, fertilisation and passage of growing embryo through fallopian tube

blastomeres is called a morula (Figure 2.11e). The morula continues to divide and transforms into blastocyst (Figure 2.11g) as it moves further into the uterus. The blastomeres in the blastocyst are arranged into an outer layer called **trophoblast** and an inner group of cells attached to trophoblast called the **inner cell** mass. The trophoblast layer then gets attached to the endometrium and the inner cell mass gets differentiated as the embryo. After attachment, the uterine cells divide rapidly and covers the blastocyst. As a result, the blastocyst becomes embedded in the endometrium of the uterus (Figure 2.11 step H). This is called **implantation** and it leads to pregnancy.

AR ✓

Question



State true (T) or false (F).

- i. The ovum released by the ovary is transported to the ampullary region where fertilisation takes place.
- ii. Fertilisation can only occur if the ovum and sperms are transported simultaneously to the infundibulum region.
- iii. All copulations lead to fertilisation and pregnancy.
- iv. The process of fusion of a sperm with an ovum is called fertilization.

A i – T, ii – T, iii– F, iv – F

B i – F, ii – T, iii– F, iv – T

C i – T, ii – T, iii– T, iv – F

D i – T, ii – F, iii– F, iv – T

———— **FOR NOTES & DPP CHECK DESCRIPTION** ————

Question

Identify A, B, C, D correctly.

A

A – Zona pellucida
B – Sperm
C – Perivitelline space
D – Corona radiata

B

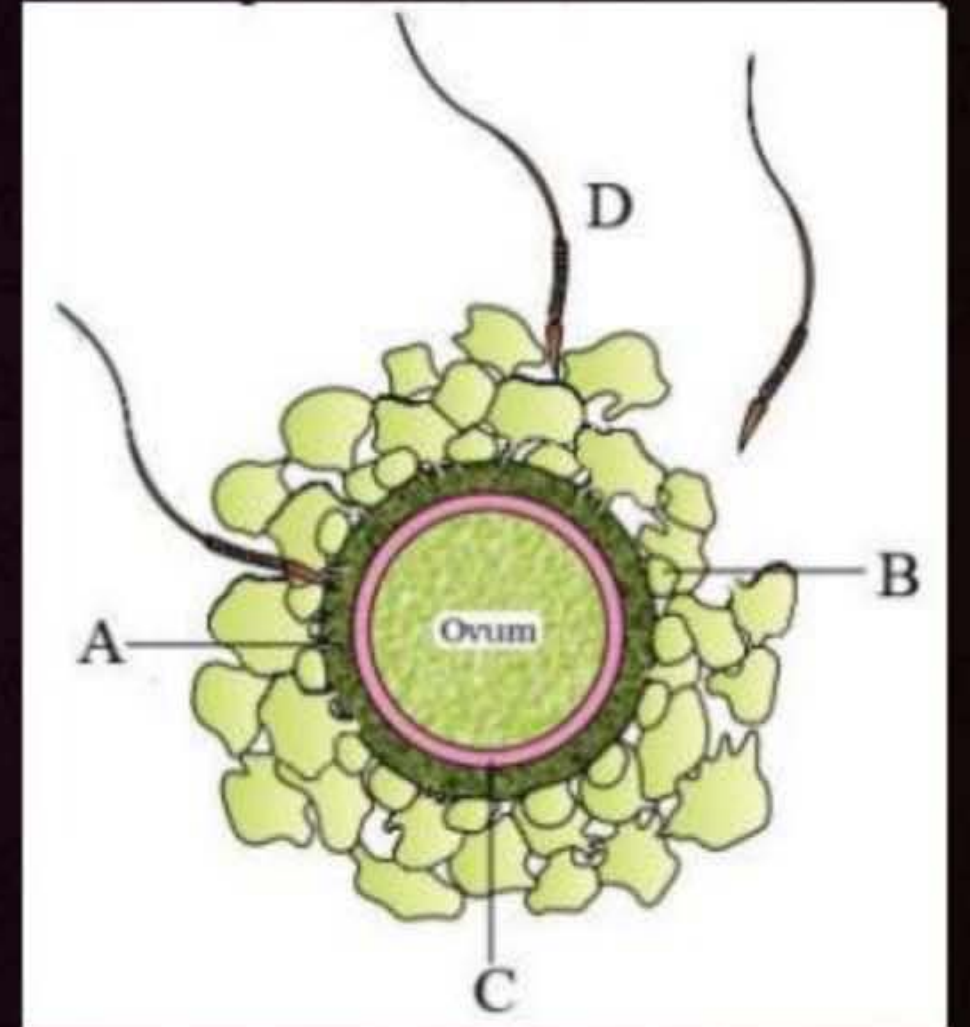
A – Zona pellucida
B – Corona radiata
C – Perivitelline space
D – Sperm

C

A – Zona pellucida
B – Corona radiata
C – Sperm
D – Perivitelline space

D

A – Corona radiata
B – Zona pellucida
C – Perivitelline space
D – Sperm



————— **FOR NOTES & DPP CHECK DESCRIPTION** —————

Question



Match the following.

A a – (iii), b – (iv), c – (i), d – (ii)

B a – (iv), b – (iii), c – (i), d – (ii)

C a – (ii), b – (iv), c – (i), d – (iii)

D a – (i), b – (iv), c – (iii), d – (ii)

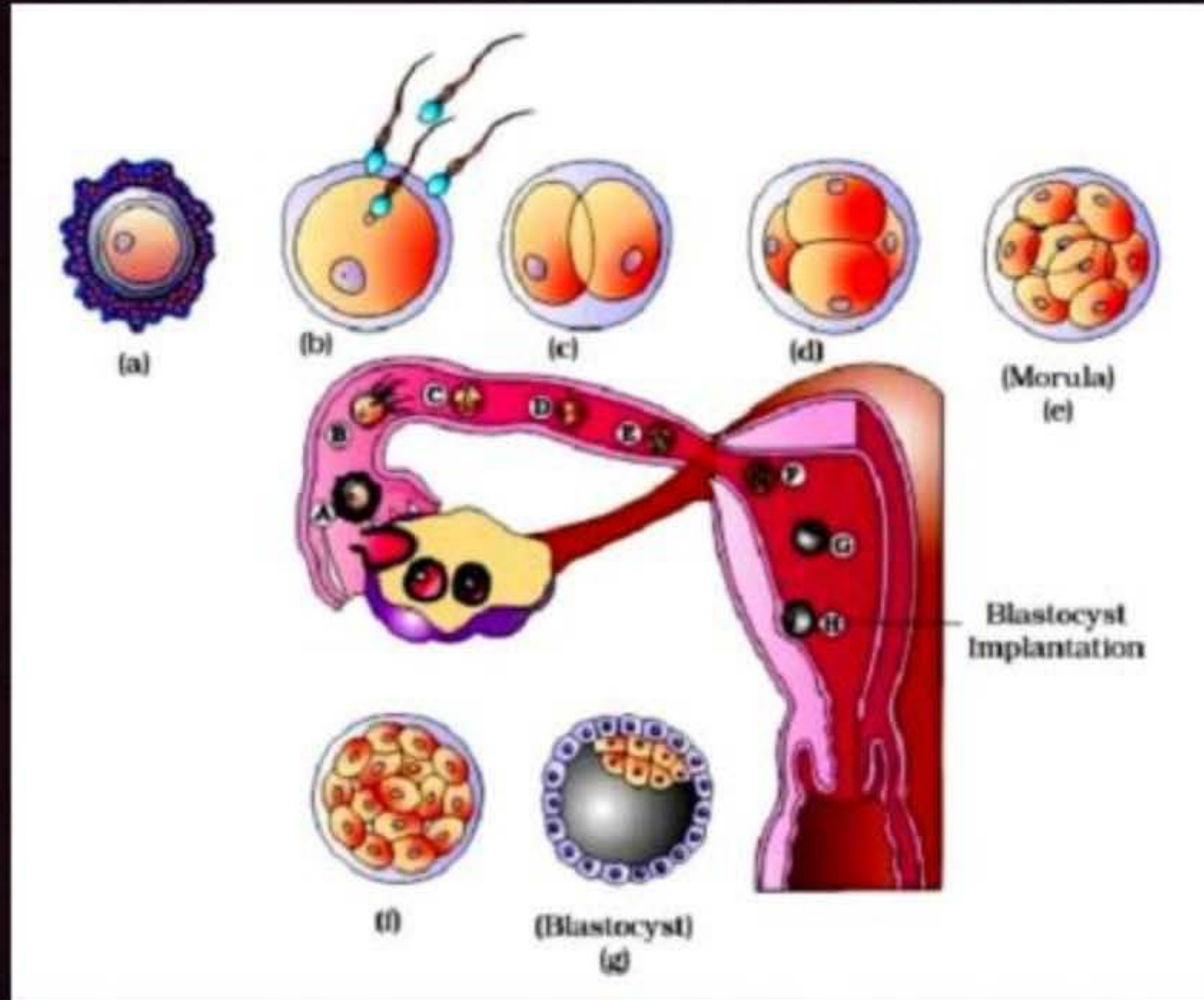
| | | | |
|----|------------|-------|--|
| a. | Ovum | (i) | 8-16 celled embryo formed in fallopian tube |
| b. | Zygote | (ii) | Implantation occurs in the uterine endometrium |
| c. | Morula | (iii) | Formed after sperm entry |
| d. | Blastocyst | (iv) | Single, diploid cell formed as a result of fertilisation |

————— **FOR NOTES & DPP CHECK DESCRIPTION** —————

Question

Identify the structure X correctly.

- A** Morula
- B** Blastocyst
- C** Ootid
- D** Blastomere



————— **FOR NOTES & DPP CHECK DESCRIPTION** —————

Question



Select the correct statements.

- I. The cycle of events starting from one menstruation till the next one is called the menstrual cycle.
- II. The menstrual phase lasts for 12–14 days.
- III. The menstrual flow results due to breakdown of endometrial lining of the uterus.
- IV. Menstruation only occurs if the released ovum is not fertilised.

A I, II and III only

B I, III and IV only

C I and IV only

D I, II, III and IV

———— **FOR NOTES & DPP CHECK DESCRIPTION** ————



Immunity Booster
= Short notes

* Trophoblast Cells

1. Secrete Enzymes for Zona pellucida digestion
2. Secrete hCG Hormone
 - Maintain Corpus luteum
 - Basis of Urine Preg Test

* ECTOPIC PREGNANCY

- Implantation at Site, other than Normal Site,
- due to Pre-mature rupture of Zona pellucida

Trophoblast layer gets attached to Endometrium, then uterine cells divide rapidly and cover blastocyst → Becomes Embedded in Endometrium
Day 6/7 fertilisation = IMPLANTATION, leads to Preg



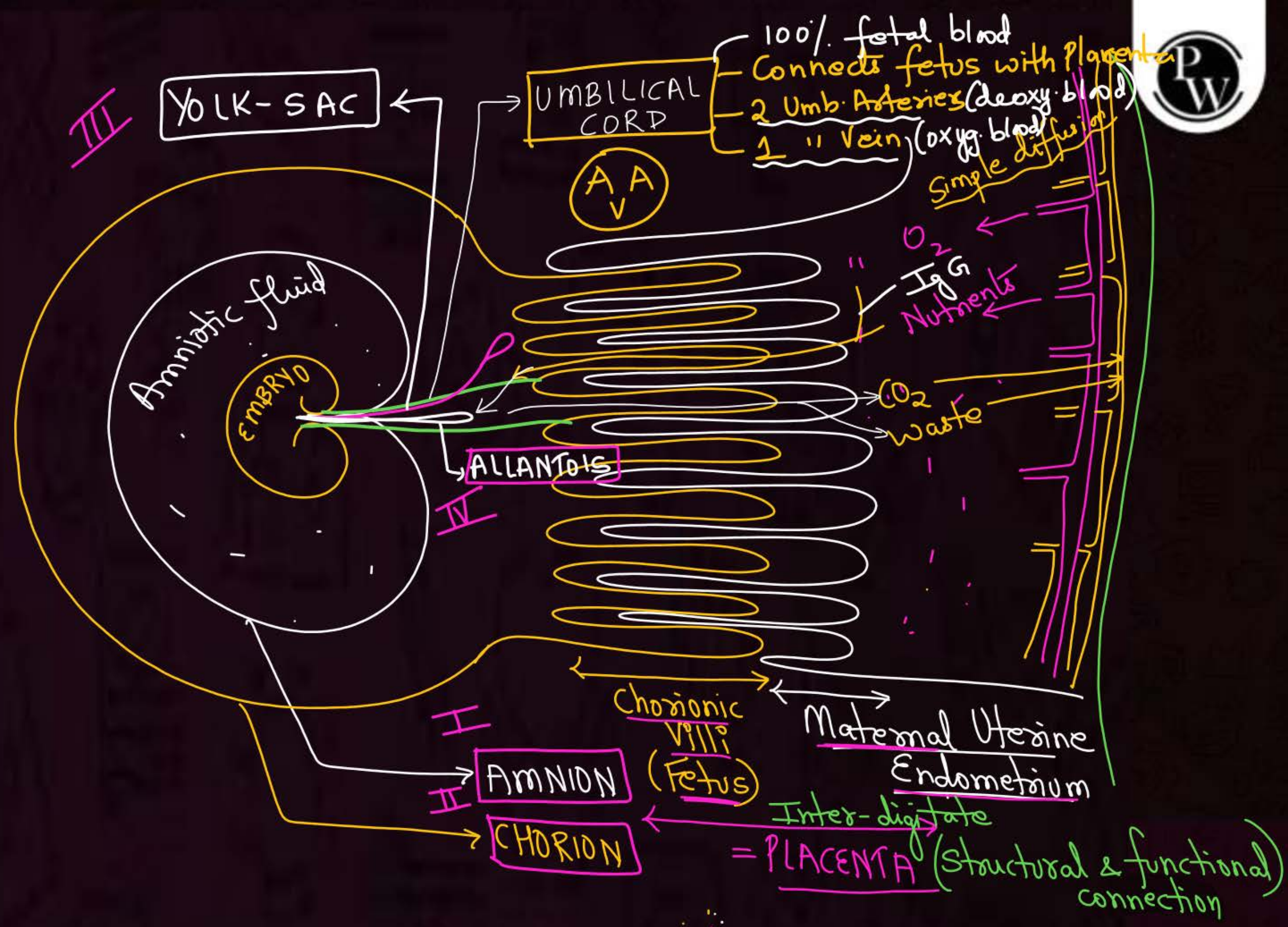
Immediately, after Implantation, ICM differentiate into Outer Ectoderm, Inner Endo & middle Mesoderm

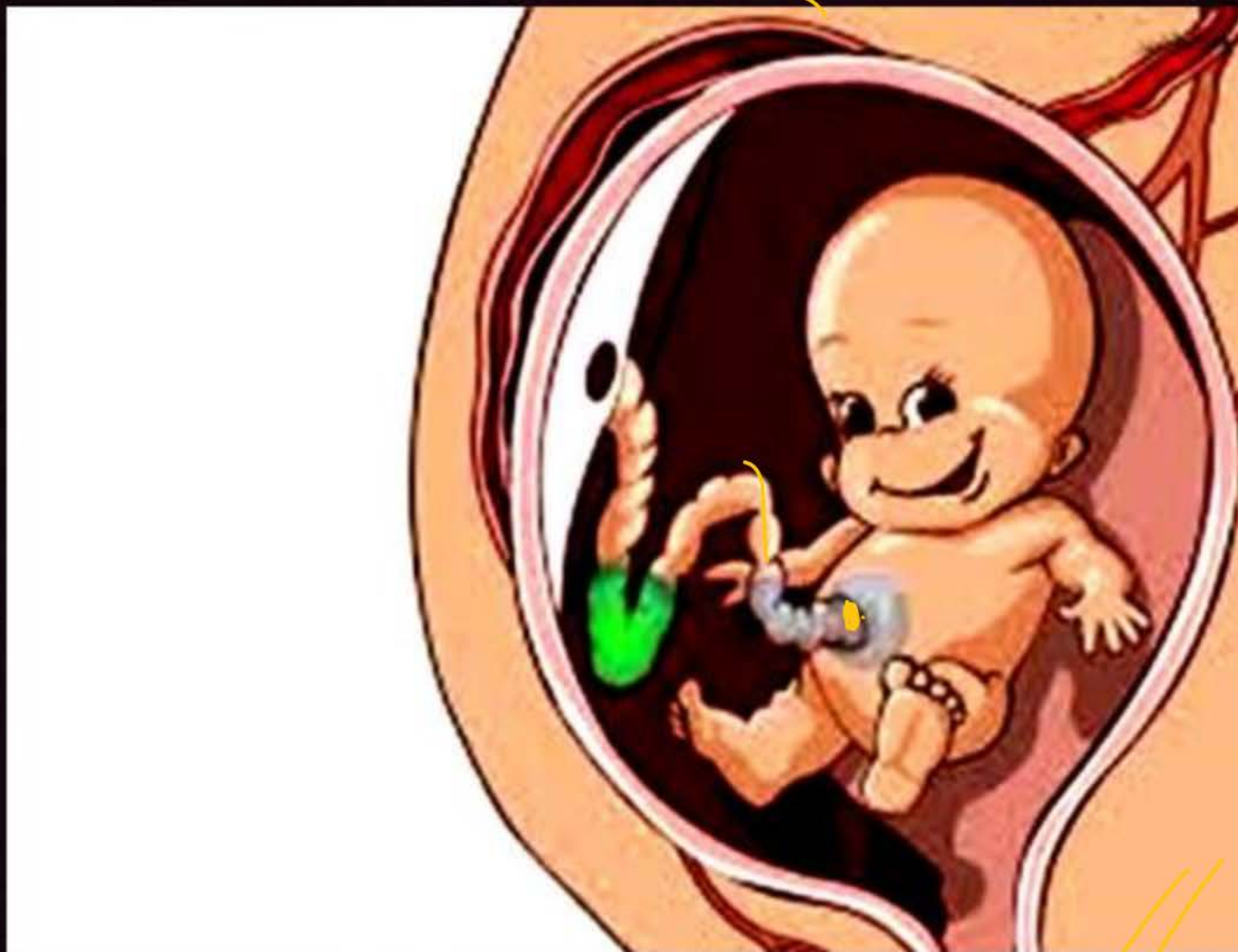ICM (Embryo) has STEM CELLS → All tissues & Organs

EXTRA-EMBRYONIC MEMBRANES :- 4

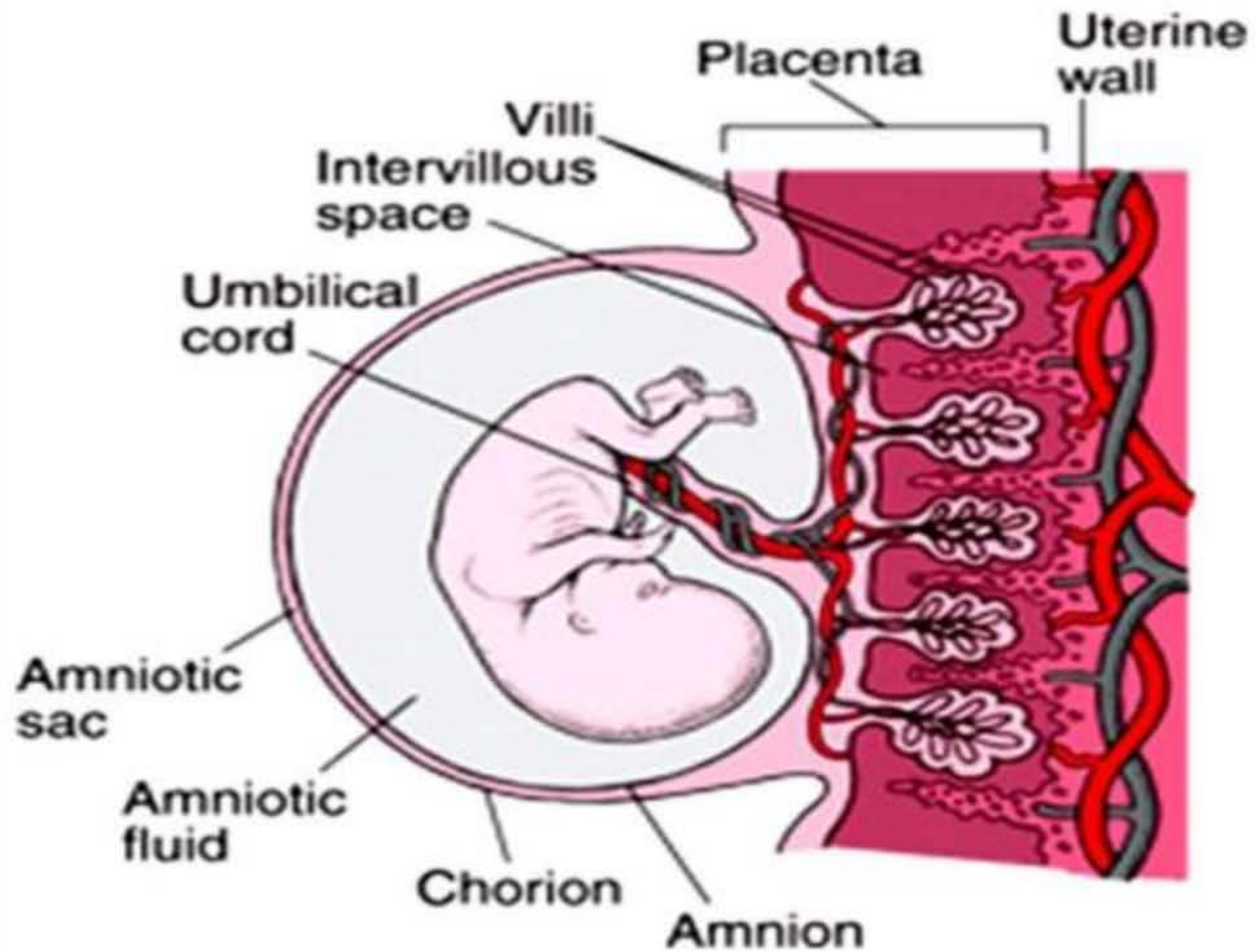
1. CHORION = Mesoderm + Trophoblast; forms placenta
2. AMNION = Mesoderm + Ectoderm; prevent from desiccation
PYQ, Out of NCERT
3. YOLK-SAC = Mesoderm + Endoderm; Haemopoietic, Germ Cells
4. ALLANTOIS = Mesoderm + Endoderm; Umbilical vessels







———— FOR NOTES & DPP CHECK DESCRIPTION ————



———— **FOR NOTES & DPP CHECK DESCRIPTION** ————



Immunity Booster = Short notes



* PLACENTA

• Structural & functional unit between developing fetus & maternal body

1. Supply O_2 & Nutrients to fetus

2. Removal of CO_2 & Waste from fetus

3. Diffusion of IgG Antibody into fetus

4. Endocrine gland - produce hormones

* Embryonic development

1. After 1 month
↳ Heart formed

2. By end of 2nd month - limbs, digits
3. By end of 3rd month - External genitalia
Major Organ System

4. By end of 5th month
↳ 1st fetal movement
↳ Hairs on head

6. By end of 6th month (2nd trimester)
↳ body covers fine hairs
↳ Eye - Lashes formed
↳ Eye - lids separate

7. By end of 9 months: fetus ready for delivery

Deeds Time of delivery

PYQ
OUT OF NCERT

E_2 / Progesterone ratio ↑

↳ Estrogen Synthesis

↳ fetal Adrenal gland

↳ CRH

hCACTH
human chorionic ACTH

PLACENTAL HORMONES

6. hCG
↳ Maintain Corpus luteum

1. Estrogen

2. Progesterone

3. Relaxin (later)
(from CL also) preg

4. hPL: milk secretion
human Placental Lactogen

5. hCT

↳ Stimulate Maternal thyroid gland

↳ Thyroid hormones

↳ Fetal development

UMBILICAL CORD

• Connects fetus to Placenta

• 2 Umbilical Arteries

• 1 Umb. Vein

• 100% fetal blood

Chorionic + Endometrium Villi = PLACENTA



Immunity Booster = Short Notes

* GESTATION

- Average duration of Human Pregnancy
- 9 months
- Dogs: 52-65 days
- Cats
- Elephant: 18-22 months (longest)

LACTATION

- Milk production, start towards End of Pregnancy; feed newborn
- COLOSTRUM = Initial few days milk
→ Several Antibodies
- MILK SECRETION $\xrightarrow{\text{IgA}}$ Prolactin, hPL
- MILK EJECTION/LET-DOWN \rightarrow OXYTOCIN



Parturition = Delivery of baby (foetus) or Expulsion of baby out of Uterus, through birth Canal
 { Complex Neuro-endocrine mechanism
 Signals for Parturition Originate from Both:

(a) Fully developed foetus (b) Placenta

PVA
out of NCE $\text{PGF}_{2\alpha}$
(Prostaglandins)

(FER) Fetal Ejection Reflex
= Mild Uterine Contractions

CRH

Fetal Adrenal Cortex

Estrogen $\uparrow\uparrow$ *

\rightarrow Oxytocin release from Maternal Post. pituitary
 (further Secretion)
Stronger Uterine Contractions

- Estrogen/Progesterone \uparrow
- \uparrow Oxytocin Receptors on Uterine Muscle
- Cervical dilatation
- Secrete PROSTAGLANDINS from Uterine Cells

- Child delivery
- Soon after, Placenta expelled out of Uterus

* RELAXIN
Hormone

[Corpus luteum + Placenta of Ovary]

\rightarrow Relax Pubic ligaments \rightarrow Easy Parturition

2.6 PREGNANCY AND EMBRYONIC DEVELOPMENT

After implantation, finger-like projections appear on the trophoblast called **chorionic villi** which are surrounded by the uterine tissue and maternal blood. The chorionic villi and uterine tissue become interdigitated with each other and jointly form a structural and functional unit between developing embryo (foetus) and maternal body called **placenta** (Figure 2.12).

The placenta facilitate the supply of oxygen and nutrients to the embryo and also removal of carbon dioxide and excretory/waste materials produced by the embryo. The placenta is connected to the embryo through an umbilical cord which helps in the transport of substances to and from the embryo. Placenta also acts as an endocrine tissue and produces several hormones like human chorionic gonadotropin (hCG), human placental lactogen (hPL), estrogens, progestogens, etc. In the later phase of pregnancy, a hormone called **relaxin** is also secreted by



AR

the ovary. Let us remember that hCG, hPL and relaxin are produced in women only during pregnancy. In addition, during pregnancy the levels of other hormones like estrogens, progestogens, cortisol, prolactin, thyroxine, etc., are increased several folds in the maternal blood. Increased production of these hormones is essential for supporting the fetal growth, metabolic changes in the mother and maintenance of pregnancy.

hC
ACTH
hCT

Umbilical cord with its vessels

AR

Immediately after implantation, the inner cell mass (embryo) differentiates

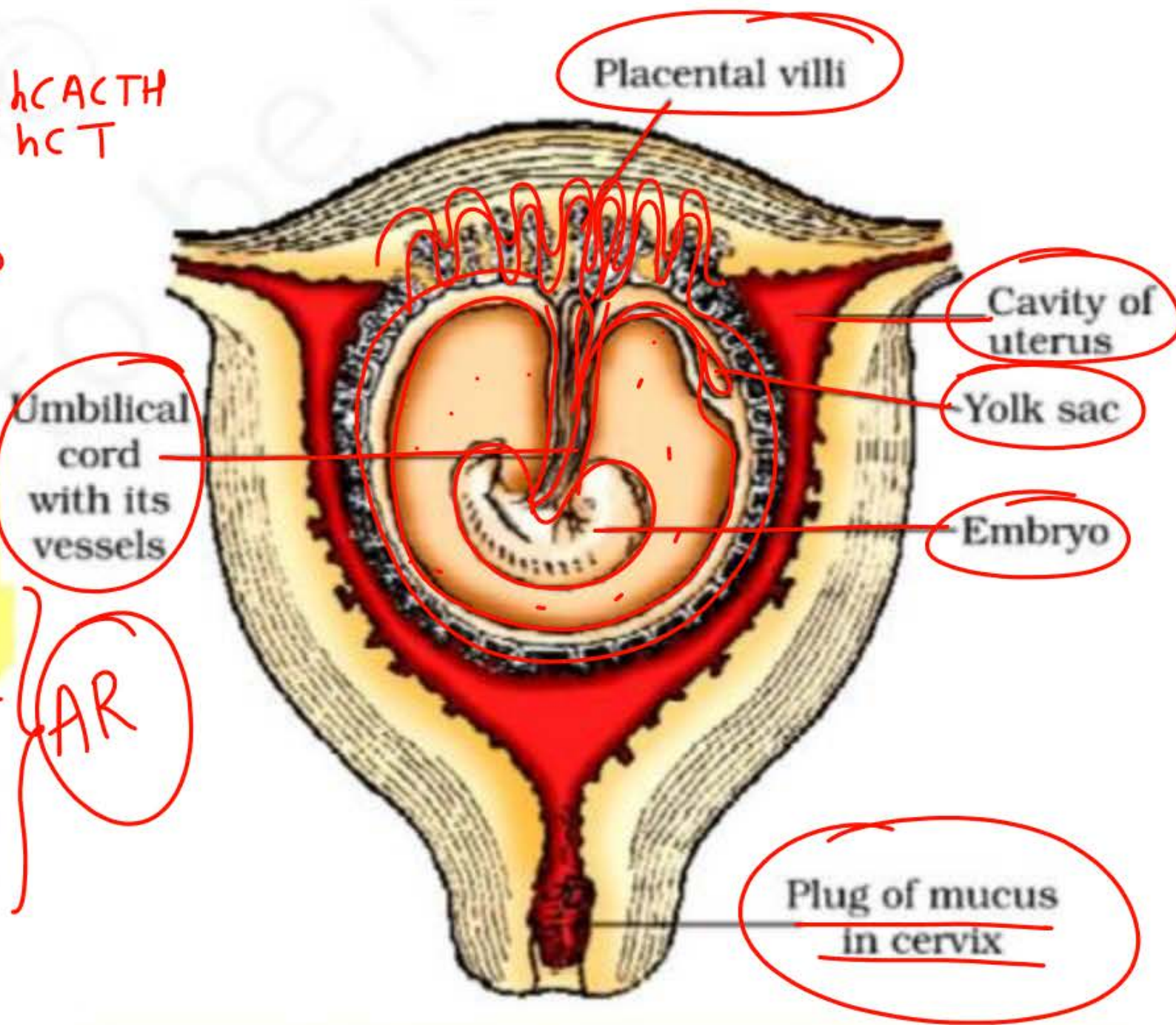


Figure 2.12 The human foetus within the uterus

into an outer layer called **ectoderm** and an inner layer called **endoderm**. A **mesoderm** soon appears between the ectoderm and the endoderm. These three layers give rise to all tissues (organs) in adults. It needs to be mentioned here that the inner cell mass contains certain cells called **stem** cells which have the potency to give rise to all the tissues and organs.

What are the major features of embryonic development at various months of pregnancy? The human pregnancy lasts 9 months. *Do you know for how many months pregnancy last in dogs, elephants, cats?* Find out. In human beings, after one month of pregnancy, the embryo's heart is formed. The first sign of growing foetus may be noticed by listening to the heart sound carefully through the stethoscope. By the end of the

second month of pregnancy, the foetus develops limbs and digits. By the end of 12 weeks (first trimester), most of the major organ systems are formed, for example, the limbs and external genital organs are well-developed. The first movements of the foetus and appearance of hair on the head are usually observed during the fifth month. By the end of about 24 weeks (end of second trimester), the body is covered with fine hair, eye-lids separate, and eyelashes are formed. By the end of nine months of pregnancy, the foetus is fully developed and is ready for delivery.

Question

State true (T) or false (F)

- i. Placenta allows mixing of maternal and fetal blood
- ii. Foetus is most susceptible to teratogens during first trimester of pregnancy
- iii. Relaxin is produced only by placenta
- iv. Folic acid and cyanocobalamin vitamins are essential for foetal development

A i – T, ii – T, iii– F, iv – F

B i – F, ii – T, iii– F, iv – T

C i – T, ii – T, iii– T, iv – F

D i – T, ii – F, iii– F, iv – T

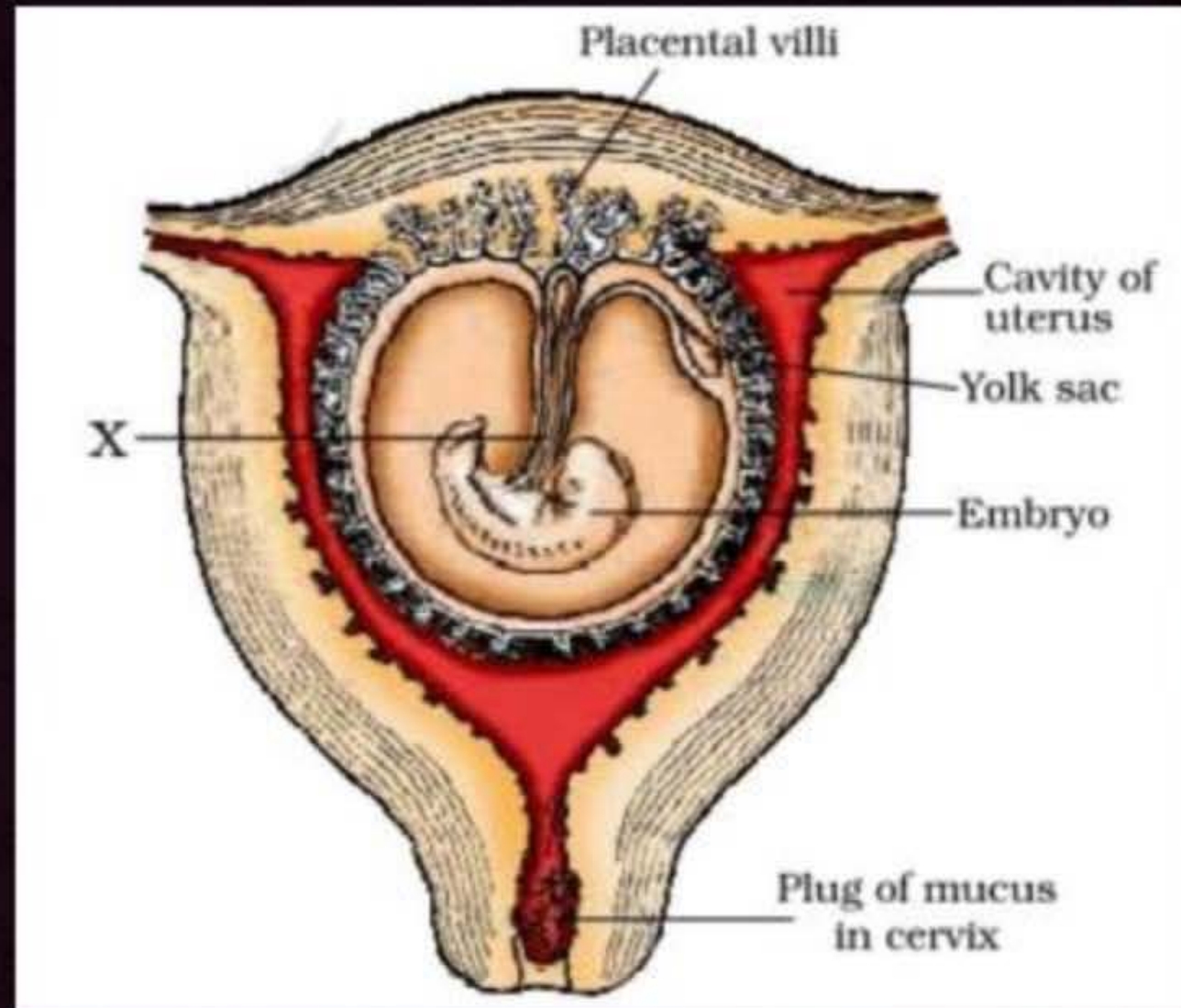
———— **FOR NOTES & DPP CHECK DESCRIPTION** ————

Question



Identify the structure X correctly.

- A** Amnion
- B** Chorion
- C** Umbilical cord
- D** Fetal lung



————— **FOR NOTES & DPP CHECK DESCRIPTION** —————

Question



Match the following

A a – iii, b – iv, c – i, d – ii

B a – iv, b – iii, c – i, d – ii

C a – ii, b – iv, c – i, d – iii

D a – i, b – iv, c – iii, d – ii

| Column-I | | Column-II | |
|----------|--------------------------------|-----------|----------------------------------|
| a. | By the end of second trimester | i. | Embryo's heart is formed |
| b. | By the end of nine months | ii. | Body is covered with fine hair |
| c. | After one month of pregnancy | iii. | Foetus develops limbs and digits |
| d. | By the end of the second month | iv. | Foetus is fully developed |

————— **FOR NOTES & DPP CHECK DESCRIPTION** —————

Question

State true (T) or false (F)

- i. Oxytocin causes stronger uterine contractions
- ii. Oxytocin is called birth hormone
- iii. Oxytocin acts on the uterine muscles
- iv. Oxytocin is produced by pituitary gland

A i – T, ii – T, iii – F, iv – F

B i – F, ii – T, iii – F, iv – T

C i – T, ii – T, iii – T, iv – F

D i – T, ii – F, iii – F, iv – T

———— **FOR NOTES & DPP CHECK DESCRIPTION** ————

Question



Match the following.

A a – iii, b – iv, c – i, d – ii

B a – iv, b – iii, c – i, d – ii

C a – ii, b – iv, c – i, d – iii

D a – i, b – iv, c – iii, d – ii

| Column-I | | Column-II | |
|----------|------------------------|-----------|-------------------------------------|
| a. | IgA | i. | Cortisol |
| b. | Prolactin | ii. | Placenta and fully developed foetus |
| c. | Foetal adrenal cortex | iii. | Maternal pituitary |
| d. | Foetal ejection reflex | iv. | Colostrum |

————— **FOR NOTES & DPP CHECK DESCRIPTION** —————

2.7 PARTURITION AND LACTATION

The average duration of human pregnancy is about 9 months which is called the gestation period. Vigorous contraction of the uterus at the end of pregnancy causes expulsion/delivery of the foetus. This process of delivery of the foetus (childbirth) is called **parturition**. Parturition is induced by a complex neuroendocrine mechanism. The signals for parturition originate from the fully developed foetus and the placenta which induce mild uterine contractions called **foetal ejection reflex**. This triggers release of oxytocin from the maternal pituitary. Oxytocin acts on the uterine muscle and causes stronger uterine contractions, which in turn stimulates further secretion of oxytocin. The stimulatory reflex between

the uterine contraction and oxytocin secretion continues resulting in stronger and stronger contractions. This leads to expulsion of the baby out of the uterus through the birth canal – parturition. Soon after the infant is delivered, the placenta is also expelled out of the uterus. *What do you think the doctors inject to induce delivery?*

The mammary glands of the female undergo differentiation during pregnancy and starts producing milk towards the end of pregnancy by the process called **lactation**. This helps the mother in feeding the new-born. The milk produced during the initial few days of lactation is called **colostrum** which contains several antibodies absolutely essential to develop resistance for the new-born babies. Breast-feeding during the initial period of infant growth is recommended by doctors for bringing up a healthy baby.

AR

Question



Identify A, B, C, D correctly

The process of childbirth is called __A__ which is induced by a complex neuroendocrine mechanism involving cortisol, estrogens and __B__ The stimulatory reflex between the uterine __C__ and oxytocin secretion continues resulting in stronger and stronger contractions. This leads to expulsion of the baby out of the uterus through the __D__.

1

A – Parturition
B – Oxytocin
C – Contraction
D – Birth canal

2

A – Lactation
B – Oxytocin
C – Relaxation
D – Birth canal

3

A – Parturition
B – Oxytocin
C – Relaxation
D – Cervix

4

A – Parturition
B – Prolactin
C – Contraction
D – Vagina

Ans (1)

QUESTION (2019)



Select the correct sequence for transport of sperm cells in male reproductive system.

- A** Testis → Epididymis → Vasa efferentia → Rete testis → Inguinal canal → Urethra
- B** Seminiferous tubules → Rete testis → Vasa efferentia → Epididymis → Vas deferens → Ejaculatory duct → Urethra → Urethral meatus
- C** Seminiferous tubules → Vasa efferentia → Epididymis → Inguinal canal → Urethra
- D** Testis → Epididymis → Vasa efferentia → Vas deferens → Ejaculatory duct → Inguinal canal → Urethra → Urethral meatus

————— **FOR NOTES & DPP CHECK DESCRIPTION** —————

QUESTION (2016-II)

Repeat PYQ

Which of the following depicts the correct pathway of transport of sperms?

- A** Rete testis → Vas deferens → Efferent ductules → Epididymis
- B** Efferent ductules → Rete testis → Vas deferens → Epididymis
- C** Rete testis → Efferent ductules → Epididymis → Vas deferens
- D** Rete testis → Epididymis → Efferent ductules → Vas deferens

————— FOR NOTES & DPP CHECK DESCRIPTION —————

Question (2015, 14)

Repeat PYQ

The shared terminal duct of the reproductive and urinary system in the human male is:

- A** Urethra
- B** Ureter (Frog)
- C** Vas deferens
- D** Vasa efferentia

————— FOR NOTES & DPP CHECK DESCRIPTION —————

Question (2017-Delhi)

Capacitation occurs in:

Out of NCERT

- A** Rete testis
- B** Epididymis
- C** Vas deferens
- D** Female Reproductive tract

————— **FOR NOTES & DPP CHECK DESCRIPTION** —————

Question (2015)

Capacitation refers to changes in the:

*Out of NCERT
Topic repeat*

- ☒ **A** Ovum after fertilisation
- ☒ **B** Sperm after fertilisation
- ☒ **C** Sperm before fertilisation
- ☒ **D** Ovum before fertilisation

———— **FOR NOTES & DPP CHECK DESCRIPTION** ————

Question (2022)



Which of the following statements are true for spermatogenesis but do not hold true for Oogenesis?

- A. It results in the formation of haploid gametes (Both)
 - B. Differentiation of gamete occurs after the completion of meiosis Only spermatogenesis
 - C. Meiosis occurs continuously in a mitotically dividing stem cell population False
 - D. It is controlled by the Luteinising hormone (LH) and Follicle Stimulating Hormone (FSH) secreted by the anterior pituitary Both
 - E. It is initiated at puberty → Only Spermatogenesis
- Choose the most appropriate answer from the options given below.

A B, C and E only ✓

B C and E only ✗

C B and C only ✗

D B, D and E only ✗

———— FOR NOTES & DPP CHECK DESCRIPTION ————

Question (2022)

At which stage of life the oogenesis process is initiated?

*Same topic
Same year*

- A** Adult
- B** Puberty
- C** Embryonic development stage
- D** Birth

————— **FOR NOTES & DPP CHECK DESCRIPTION** —————

Question (2022)



Given below are two statements:

Statement I: The release of sperms into the seminiferous tubules is called spermiation.

Statement II: Spermiogenesis is the process of formation of sperms from spermatogonia.

In the light of the above statements, choose the most appropriate answer from the options given below.

- ☒ **A** Statement I is incorrect but Statement II is correct
- ☐ **B** Both Statement I and Statement II are correct
- ☐ **C** Both statement I and statement II are incorrect
- ☒ **D** Statement I is correct but Statement II is incorrect

———— **FOR NOTES & DPP CHECK DESCRIPTION** ————

NCERT - from X

Same topic
Same yr.

Spermatid

Question (2020)

Meiotic division of the secondary oocyte is completed:

- A** At the time of copulation ~~X~~
- B** After zygote formation ~~X~~
- C** ✓ At the time of fusion of a sperm with an ovum
- D** Prior to ovulation

————— **FOR NOTES & DPP CHECK DESCRIPTION** —————

Question (2020-Covid)

Select the correct option of haploid cells from the following groups:

- A** ✓ Secondary spermatocyteⁿ, First polar bodyⁿ, Ovumⁿ
- B** Spermatogonia²ⁿ, Primary spermatocyte²ⁿ, Spermatidⁿ
- C** Primary spermatocyte²ⁿ, Secondary spermatocyteⁿ, Second polar bodyⁿ
- D** Primary oocyte²ⁿ, Secondary oocyteⁿ, Spermatidⁿ

———— FOR NOTES & DPP CHECK DESCRIPTION ————

Question (2019)

Extrusion of second polar body from egg nucleus occurs:

- ☒ **A** After entry of sperm but before fertilization.
- ☐ **B** After fertilization.
- ☐ **C** Before entry of sperm into ovum.
- ☐ **D** Simultaneously with first cleavage.

Out of NCERT

———— **FOR NOTES & DPP CHECK DESCRIPTION** ————

Question (2018)

The difference between spermiogenesis and spermiation is:

- A** In spermiogenesis spermatids are formed, while in spermiation spermatozoa are formed.
- B** In spermiogenesis spermatozoa are formed, while in spermiation spermatids are formed.
- C** In spermiogenesis spermatozoa from Sertoli cells are released into the cavity of seminiferous tubules, while in spermiation spermatozoa are formed.
- D** In spermiogenesis spermatozoa are formed, while in spermiation spermatozoa are released from Sertoli cells into the cavity of seminiferous tubules.

————— FOR NOTES & DPP CHECK DESCRIPTION —————

Question (2015)

Which of the following cells during gametogenesis is normally diploid?

A ~~Spermatogonia~~ $2n$

B Secondary polar body n

C Primary polar body n

D Spermatid n

Repeat PYQ

———— FOR NOTES & DPP CHECK DESCRIPTION ————

Question (2013)

What is the correct sequence of sperm formation?

Repeat 14Q

- A** ✓ ~~Spermatogonia~~, ^{(P) → (S)} Spermatocyte, Spermatid, Spermatozoa
- B** ~~Spermatid~~, ~~Spermatocyte~~, Spermatogonia, Spermatozoa
- C** Spermatogonia, Spermatocyte, Spermatozoa, ~~Spermatid~~
- D** ~~Spermatogonia~~, ~~Spermatozoa~~, Spermatocyte, Spermatid

————— FOR NOTES & DPP CHECK DESCRIPTION —————

Question (2020)



Which of the following hormone levels will cause release of ovum (ovulation) from the graffian follicle?

- A** ~~High concentration of Progesterone~~
- B** ~~Low concentration of LH~~
- C** ~~Low concentration of FSH~~
- D** High concentration of Estrogen

↑ LH

Indirect

Midcycle (Day 14)

↑ FSH

↑ LH

↑ Estrog.

Question (2017-Delhi)

A temporary endocrine gland in the human body is:

- A** Pineal gland ✓ permanent
- B** Corpus cardiacum
- C** ✓ Corpus luteum, Placenta
- D** Corpus allatum

————— FOR NOTES & DPP CHECK DESCRIPTION —————

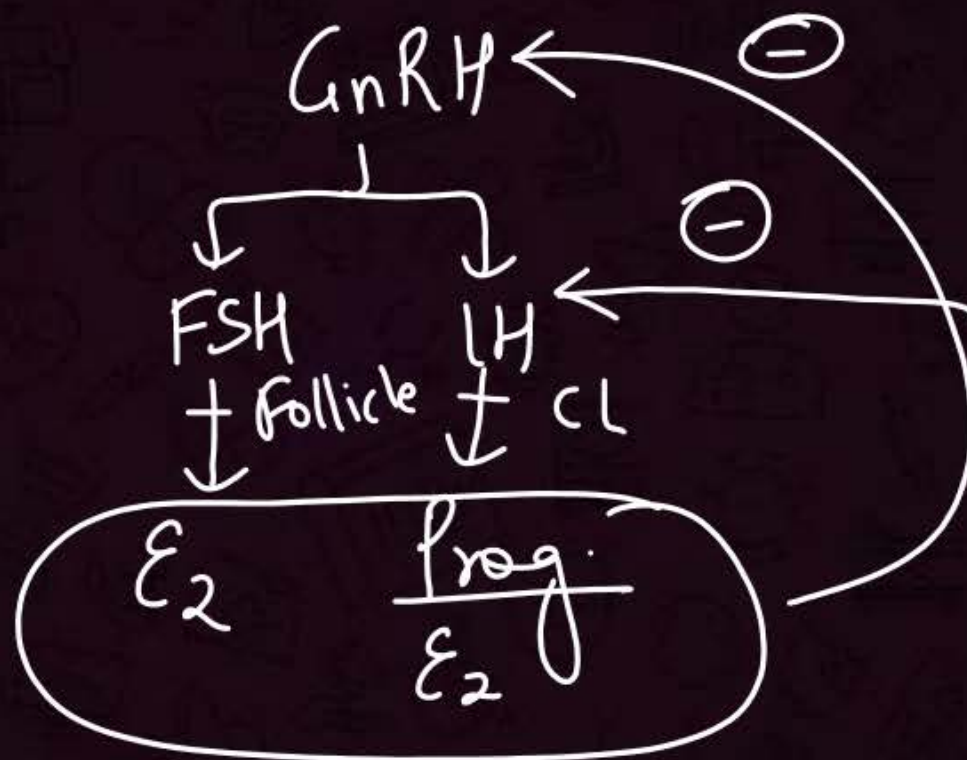
Question (2016-I)



Indirect

Changes in GnRH pulse frequency in females is controlled by circulating levels of:

- A** ~~Estrogen and progesterone~~
- B** Estrogen and inhibin
- C** Progesterone only
- D** Progesterone and inhibin



———— FOR NOTES & DPP CHECK DESCRIPTION ————

Question (2015 Re)

Which of the following events is not associated with ovulation in human female?

False

- A** Full development of Graafian follicle ✓
- B** Release of secondary oocyte ✓
- C** LH surge ✓
- D** Decrease in estradiol *Midcycle*

————— **FOR NOTES & DPP CHECK DESCRIPTION** —————

Question (2013)

Menstrual flow occurs due to lack of

- A** Vasopressin
- B** Progesterone
- C** FSH
- D** Oxytocin

———— FOR NOTES & DPP CHECK DESCRIPTION ————

Question (2021)

Receptors for sperm binding in mammals are present on:

- A** Vitelline membrane
- B** Perivitelline space
- C** ☒ Zona pellucida
- D** Corona radiata

Indirect

————— **FOR NOTES & DPP CHECK DESCRIPTION** —————

Question (2021)

Which of the following secretes the hormone, relaxin during the later phase of pregnancy?

- A** ~~Corpus luteum~~
- B** Foetus
- C** Uterus
- D** Graafian follicle

Placenta

————— FOR NOTES & DPP CHECK DESCRIPTION —————

Question (2020-Covid)

In human beings, at the end of 12 weeks (first trimester) of pregnancy, the following is observed:

- A** ☒ Most of the major organ systems are formed
 - B** The head is covered with fine hair
 - C** Movement of the foetus
 - D** Eyelids and eyelashes are formed
- 5th
- 6th

————— **FOR NOTES & DPP CHECK DESCRIPTION** —————

Question (2018)

Hormones secreted by the placenta to maintain pregnancy are:

- A** hCG, hPL, progestogens, prolactin
- B** hCG, hPL, estrogens, relaxin, oxytocin
- C** hCG, hPL, progestogens, estrogens
- D** hCG, progestogens, estrogens, glucocorticoids

————— FOR NOTES & DPP CHECK DESCRIPTION —————

Question (2018)



The amnion of mammalian embryo is derived from

Out of NCERT

A Ectoderm and mesoderm

B Endoderm and mesoderm Yolk sac, Allantois

C Mesoderm and trophoblast Chorion

D Ectoderm and endoderm

————— **FOR NOTES & DPP CHECK DESCRIPTION** —————

Question (2016-II)

Several hormones like hCG, hPL, estrogen, progesterone are produced by:

- A** Fallopian tube
- B** Pituitary
- C** Ovary
- D** Placenta

———— FOR NOTES & DPP CHECK DESCRIPTION ————

Question (2016-II)

Identify the correct statement on inhibin:

Out of NCERT

- A** Inhibits the secretion of LH, FSH and Prolactin ~~X~~
- B** ~~/~~ Is produced by granulosa cells in ovary and inhibits the secretion of FSH *only*
- C** Is produced by granulosa cells in ovary and inhibits the secretion of LH ~~X~~
- D** Is produced by nurse cells in testes and inhibits the secretion of LH ~~X~~

————— **FOR NOTES & DPP CHECK DESCRIPTION** —————

Question (2016-I)

Fertilisation in humans is practically feasible only if:

- A** The sperms are transported into vagina just after the release of ovum in fallopian tube
- B** The ovum and sperms are transported simultaneously to ampullary - isthmic junction of the fallopian tube
- C** The ovum and sperms are transported simultaneously to ampullary isthmic junction of the cervix
- D** The sperms are transported into cervix within 48 hrs of release of ovum in uterus

————— **FOR NOTES & DPP CHECK DESCRIPTION** —————

Question (2015-Re)

In human females, meiosis-II is not complete until

- A** ~~Fertilisation~~
- B** Uterine implantation ~~X~~
- C** Birth ~~X~~
- D** Puberty ~~X~~

Sperm entry
↓ m-II Comp.
Ovum

Question (2015-Re)

Which of the following layers in an antral follicle is acellular?

antral follicle

acellular

A Theca interna

B Stroma

C Zona pellucida

D Granulosa

———— FOR NOTES & DPP CHECK DESCRIPTION ————

Question (2014)



Select the correct option describing gonadotropin activity in a normal pregnant female:

Out of NCERT

FSH, LH

- ☒ **A** High level of hCG stimulates the thickening of endometrium
- ☒ **B** High level of FSH and LH stimulates the thickening of endometrium
- ☒ **C** High level of FSH and LH facilitate implantation of the embryo
- ☒ **D** High level of hCG stimulates the synthesis of estrogen and progesterone

↓ FSH
↓ LH
↑ E₂
↑ Prog.
↑ hCG

→ CL maintain

FOR NOTES & DPP CHECK DESCRIPTION

Question (2021)



Which of these is not an important component of initiation of parturition in humans?

False -

fully formed fetus

out of NCERT

Options out of NCERT

A Synthesis of prostaglandins

B Release of Oxytocin ✓

C Release of Prolactin

D Increase in estrogen and progesterone ratio ✓

Placenta → hCACTH
 $\frac{E_2}{P}$ ↑↑

FOR NOTES & DPP CHECK DESCRIPTION

Question (2015)

Which of these is not an important component of initiation of parturition in humans?

- A** Release of oxytocin ✓
- B** ~~Release of prolactin~~ ✗
- C** Increase in estrogen and progesterone ratio ✓
- D** Synthesis of prostaglandins ✓

2021
2015.

Exact
Repeat

————— FOR NOTES & DPP CHECK DESCRIPTION —————

Question (2023)

Given below are two statements:

Statement I: Vas deferens receives a duct from seminal vesicle and opens into urethra as the ejaculatory duct.

Statement II: The cavity of the cervix is called cervical canal which along with vagina forms birth canal.

In the light of the above statements, choose the correct answer from the options given below:

- ☒ A Statement I incorrect but Statement II is true.
- ☒ B Both Statement I and Statement II are true.
- ☐ C Both Statement I and Statement II are false.
- ☐ D Statement I is correct but Statement II is false.

————— **FOR NOTES & DPP CHECK DESCRIPTION** —————

Question (2023)

Given below are two statements: one is labelled as Assertion (A) and the other is labelled as Reason (R).

Assertion (A): Endometrium is necessary for implantation of blastocyst. ✓

Reason (R): In the absence of fertilization, the corpus luteum degenerates that causes disintegration of endometrium. ✓

In the light of the above statements, choose the correct answer from the options given below:

- A** (A) is false but (R) is true. ✗
- B** Both (A) and (R) are true and (R) is the correct explanation of (A). ✓
- C** Both (A) and (R) are true but (R) is NOT the correct explanation of (A). ✗
- D** (A) is true but (R) is false. ✗

————— **FOR NOTES & DPP CHECK DESCRIPTION** —————

Question (2023)

Which of the following statements are correct regarding female reproductive cycle?

- A. In non-primate mammals cyclical changes during reproduction are called oestrus cycle. Out of NCERT
 - B. First menstrual cycle begins at puberty and is called menopause. X
 - C. Lack of menstruation may be indicative of pregnancy. ✓
 - D. Cyclic menstruation extends between menarche and menopause. ✓
- Choose the most appropriate answer from the options given below:

A A, C and D only

B A and D only X

C A and B only X

D A, B and C only X

————— **FOR NOTES & DPP CHECK DESCRIPTION** —————

Question (NEET-2024)

Given below are two statements : one is labelled as Assertion A and the other is labelled as Reason R :

Assertion R : FSH acts upon ovarian follicles in female and Leydig cells in male.

Reason (R) : Growing ovarian follicles secrete estrogen in female while interstitial cells secrete androgen in male human being.

In the light of the above statements, choose the correct answer from the options given below :

- A** A is true but R is false.
- B** ~~A is false but R is true.~~
- C** Both A and R are true and R is the correct explanation of A.
- D** Both A and R are true but R is NOT the correct explanation of A.

————— **FOR NOTES & DPP CHECK DESCRIPTION** —————

Question (NEET-2024)

Which of the following is not a component of fallopian tube ?

- A** Infundibulum ✓
- B** Ampulla ✓
- C** Uterine fundus ✗
- D** Isthmus ✓

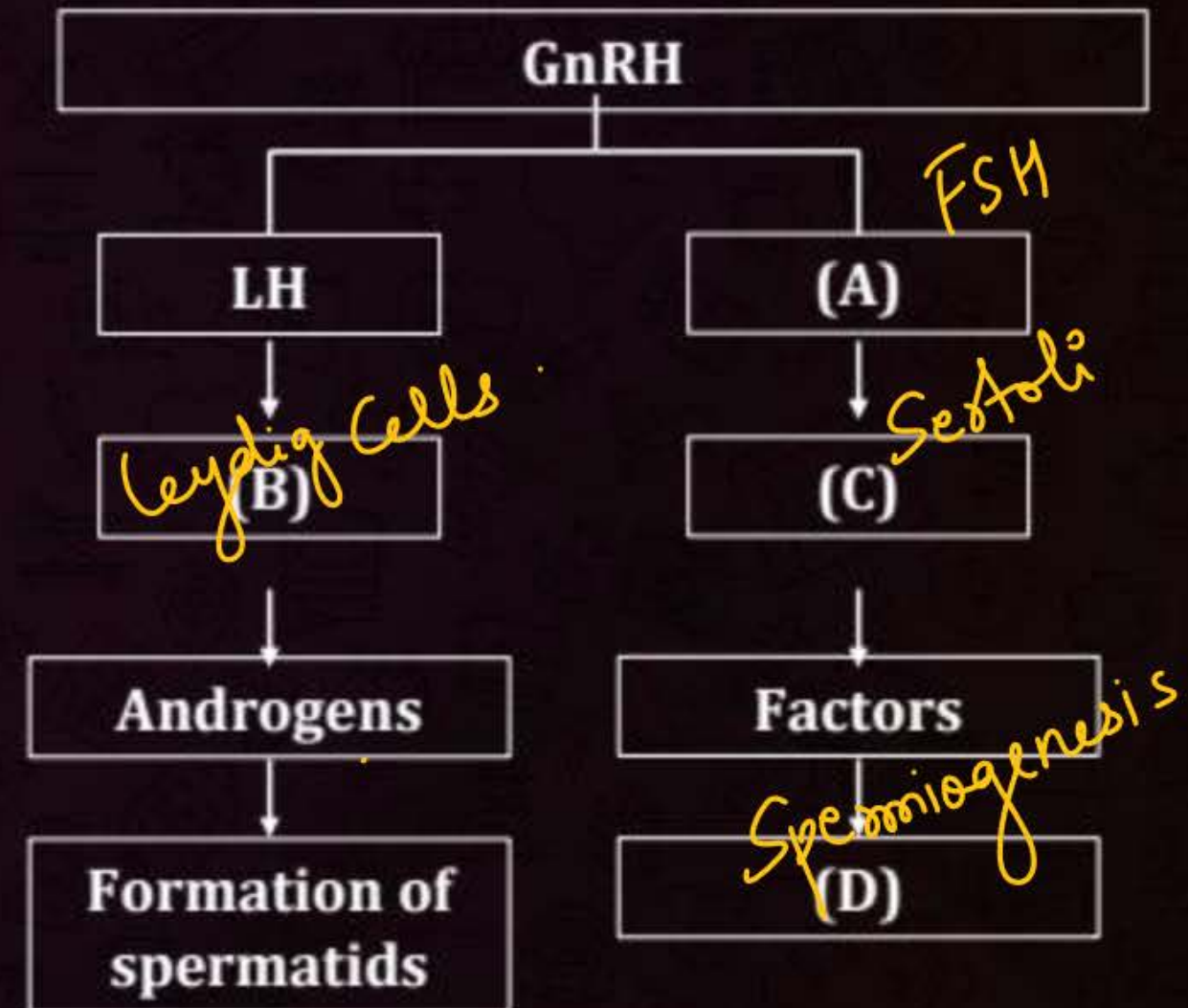
————— FOR NOTES & DPP CHECK DESCRIPTION —————

Question (NEET-2024)

Identify the correct options (A), (B), (C), (D) with respect to spermatogenesis.

Indirect
Theory → flow chart

- A** ~~FSH, Sertoli cells, Leydig cells, spermatogenesis~~
- B** ~~ICSH, Leydig cells, Sertoli cells, spermatogenesis.~~
- C** ✓ FSH, Leydig cells, Sertoli cells, spermiogenesis
- D** ~~ICSH, Interstitial cells, Leydig cells, Spermiogenesis.~~



———— FOR NOTES & DPP CHECK DESCRIPTION ————

Question (NEET-2024)

Read the following statements and choose the correct option

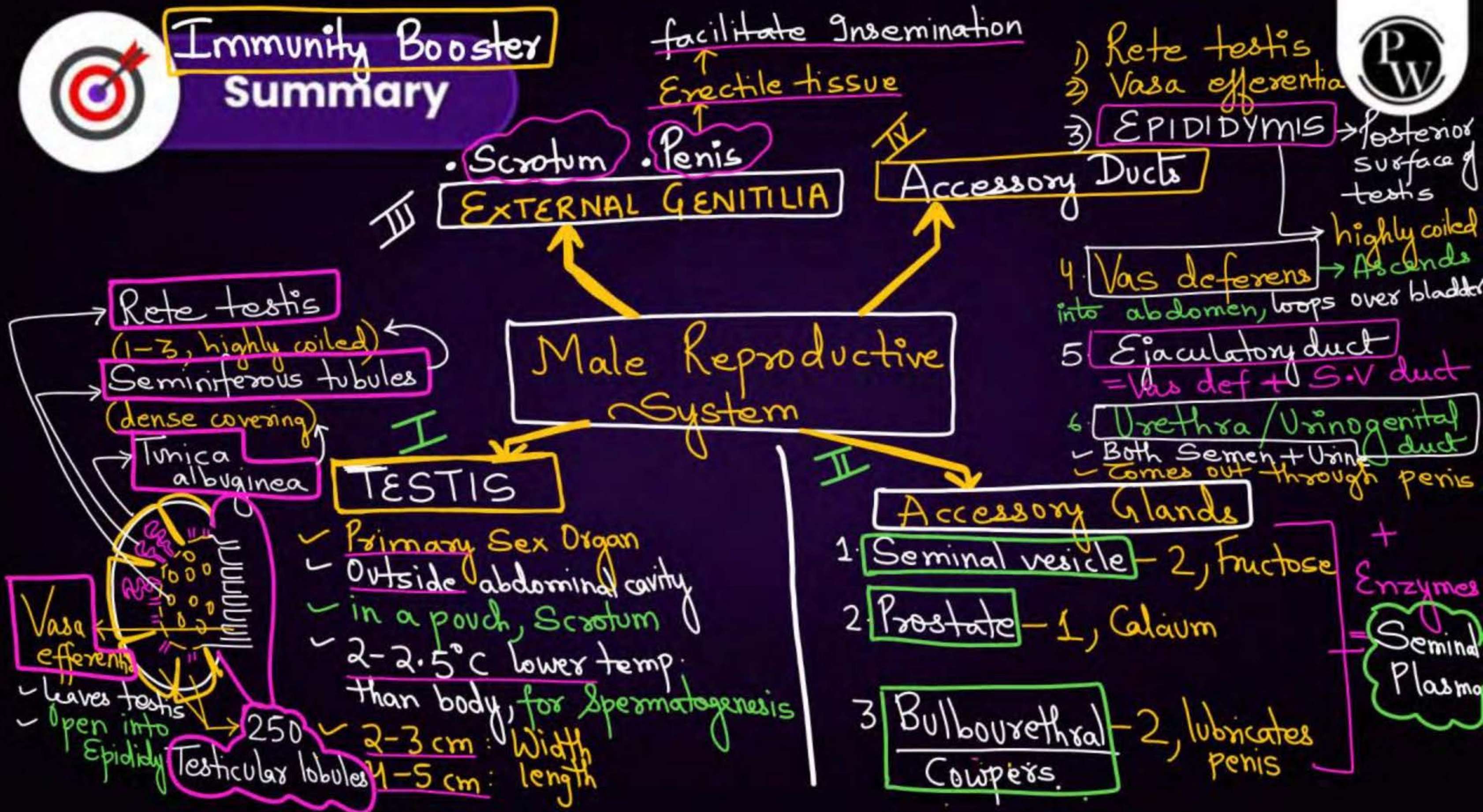
- A. The presence or absence of hymen is not a reliable indicator of virginity or sexual experience. ✓
- B. The hymen is torn during the first coitus only. ✓
However, it can also be broken by a sudden fall or jolt, insertion of a vaginal tampon etc.

- A** Both statements are correct ✗
- B** Both statements are incorrect ✗
- C** A is correct and B is incorrect ✓
- D** A is incorrect and B is correct ✗

———— **FOR NOTES & DPP CHECK DESCRIPTION** ————

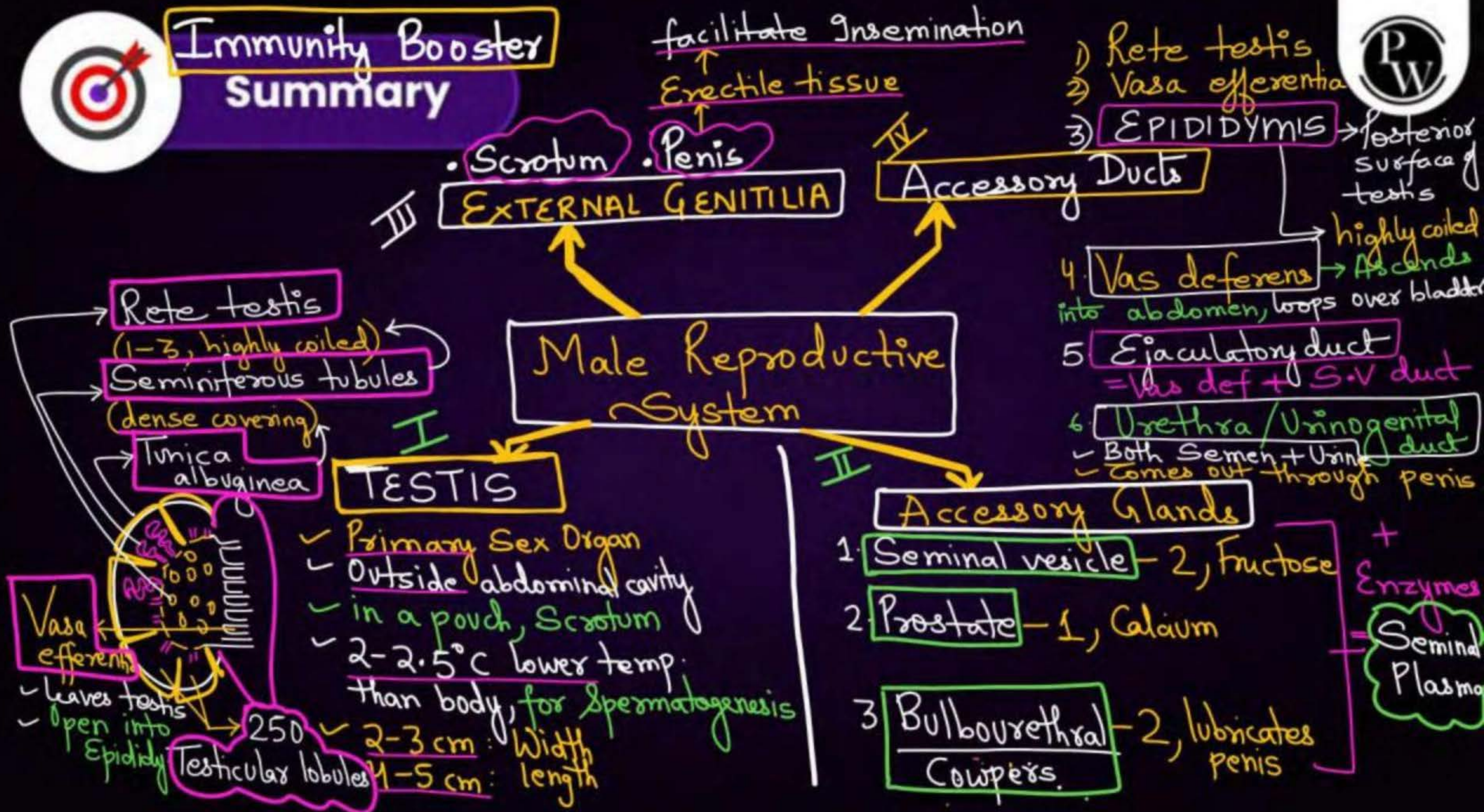


Immunity Booster Summary





Immunity Booster Summary





Immunity Booster = SHORT NOTES

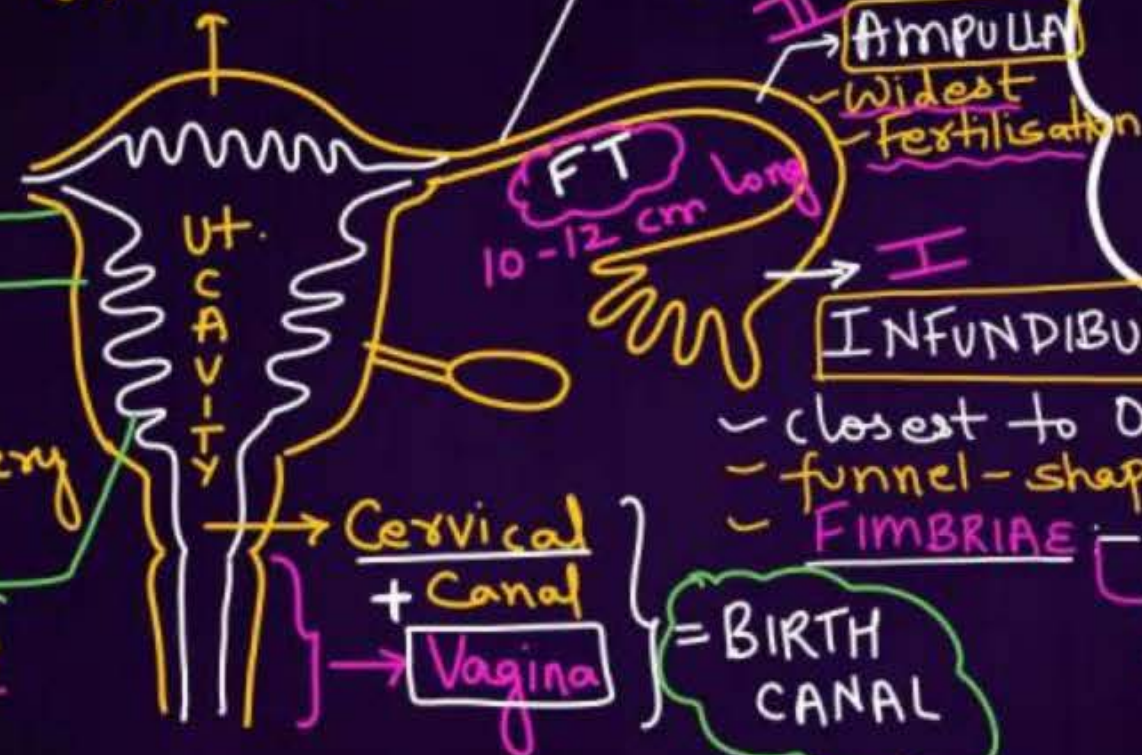
UTERUS

- Single, womb, Inverted pear
- 3 layers:

- thin, membranous outermost
- (A) **PERIMETRIUM**
- (B) **MYOMETRIUM**
- middle, thick, smooth muscle
- Contract during delivery

- (C) **ENDOMETRIUM**
- innermost, Glandular
- lines Uterine Cavity
- implantation site
- Cyclic changes during menstruation

UTERINE FUNDUS



FT

- Opens into Uterus
- narrow lumen
- last part
- ISTHMUS**

AMPULLA

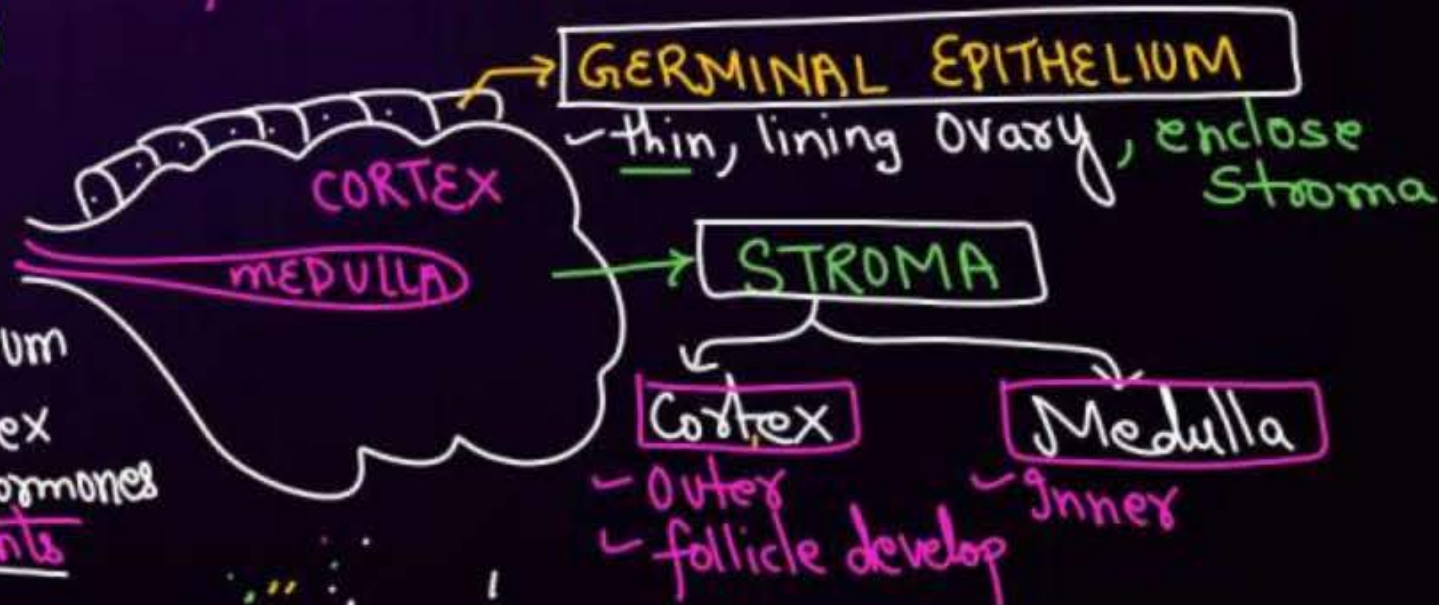
- widest
- fertilisation

INFUNDIBULUM

- closest to Ovary
- funnel-shaped
- **FIMBRIAE** - finger-like
- Collects Ovum, after Ovulation

OVARY

- 1 pair, lower abdomen
- 2-4 cm length
- **Primary Sex Organ** → Ovum
- Connected to Uterus & pelvic wall by ligaments → Sex hormones



GnRH (Hypoth)

Ant. Pituit.

FSH

Sertoli Cells

Inhibin

Spermio-genesis

LH

Leydig cells

Androgens

Spermatogenesis



Immunity Booster
= Short notes

EXTERNAL GENITALIA

1. **Mons Pubis**: Fatty tissue + skin + hair
2. **Labia Majora**:
 - Extend down from Mons pubis
 - Cover Vaginal opening
 - fleshy folds
3. **L. minora** → Paired, Under L. majora
4. **CLITORIS**:
 - tiny → finger like
 - At upper junction of L. minora
 - Above Urethral opening
5. **HYMEN**:
 - Membrane, partially covering Vaginal orifice
 - NOT a reliable indicator of Virginity

Mammary Gland

→ 1 Pair

→ Functional in ♀ mammals

→ Glandular + fat (Variable)

Each Mammary Gland

15-20 Mammary Lobes,
Milk-secreting **ALVEOLI**

Mammary tubules

Mammary tubules of each lobe,
forms **A Mammary DUCT**

Several M. Ducts Open into wider
Mammary AMPULLA

LACTIFEROUS DUCT

through which milk is sucked out





Immunity Booster = Short Notes

HUMAN SPERM

HEAD

→ ACROSOME : Cap-like, Anterior
Sperm lysins,
help in fertilisation

→ NUCLEUS : Genetic material
elongated, haploid

NECK

→ Proximal : Cleavage in
Centriole Zygote

→ Distal : Basal body
Centriole of flagella

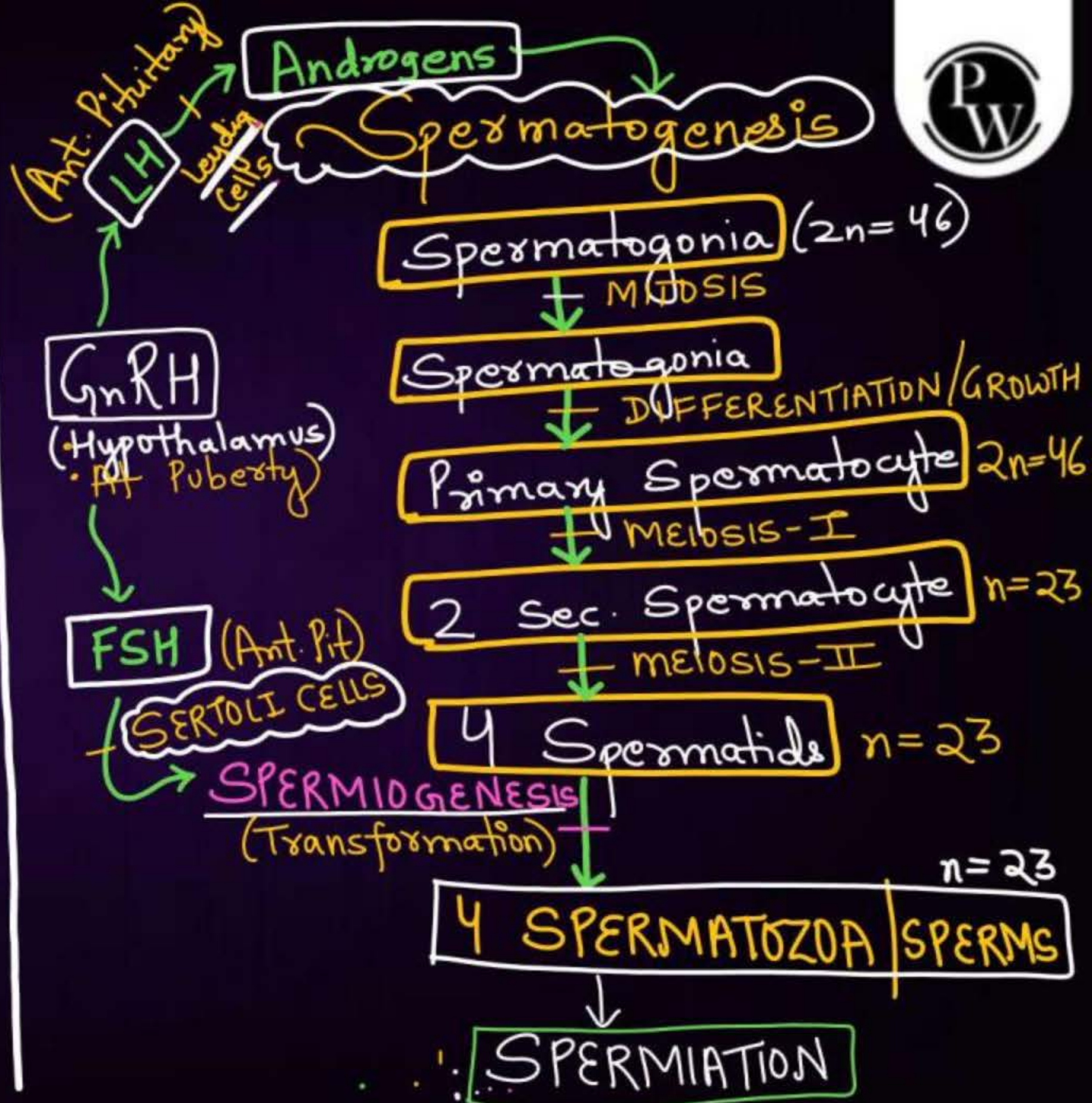
MIDDLE PIECE

→ Axoneme (9+2)

→ Mitochondria (Power
house)

TAIL

→ Flagella, Motility
(9+2)



- * Oogenesis Starts before birth
- * No More Oogonia formed/added after birth

Not in NCERT

PRIMORDIAL FOLLICLE

- Primary Oocyte (Prophase-I; diplotene)
- a single layer of Granulosa cells
- Birth → Puberty (2 lac/ovary)

At PUBERTY (FSH)

PRIMARY FOLLICLE

- Primary Oocyte (Prophase-I)
- a single layer of Granulosa cells
- 60,000 - 80,000 / Ovary (Puberty)
- NCERT: At Birth

Every Menstrual Cycle 6-10 Primary follicles develop to form (FSH)

SECONDARY FOLLICLE (2-3 every M.C)

- Primary Oocyte (Prophase-I)
- Multiple layers of Granulosa cells
- New Theca layer

ONE TERTIARY FOLLICLE

- Primary Oocyte Completes Meiosis-I
- Secondary Oocyte (Metaphase-II)
- Theca Interna & Theca Externa
- Fluid-filled cavity 'ANTRUM'
- Oocyte secretes ZONA PELLUCIDA (Acellular, Glycoprotein)

(FSH)

MATURE GRAAFIAN FOLLICLE

LH

Rupture of Graafian Follicle = OVULATION (2° Oocyte Metaphase-II)

LH In OVARY CORPUS LUTEUM

FERTILISATION

YES

NO

Into Ampullary-Isthmic Junction of Fallopian Tube

Sperm Entry

YES

NO

CL Maintain Till Parturition

Corpus Albicans

2° oocyte completes Meiosis-II

OVUM ZYGOTE

2nd Polar body (DEGENERATE)

2° oocyte degenerate



Immunity Booster
= Short Notes

MENSTRUAL CYCLE

Reproductive Cycle
in Female Primate
Mammals (Monkey, Apes, Human)



1st menstruation: **MENARCHE**
At Puberty

Last " : **MENOPAUSE**
(Around 50 yr. age)

Duration: Every 28/29 days

Menstruation occurs
ONLY if released Ovum is
NOT fertilised

No menstruation: due to
Pregnancy, Poor health, Stress

One Ovum released
in mid-cycle every month

MENSTRUAL PHASE

- ✓ Breakdown of Endometrial lining & blood vessels
- ✓ due to low Progesterone & Estrogen
- ✓ last 3-5 days

FOLLICULAR PROLIFERATIVE

- ✓ follicle → Graafian follicle
- FSH
- Endometrial Proliferation
- Estrogen

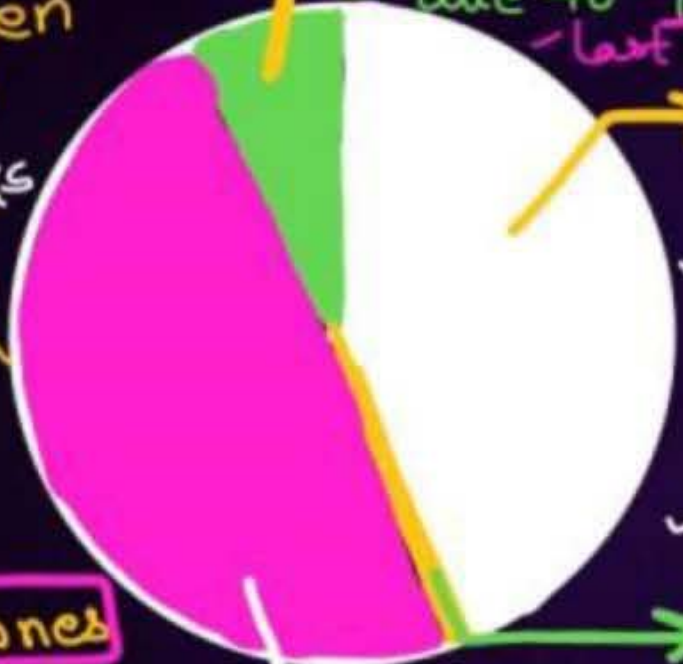
6-13 Days

OVULATORY PHASE

- ✓ Day 14th (Mid Cycle)
- ✓ due to ↑ LH (= LH SURGE)

LUTEAL / SECRETORY PHASE

- ↑ LH → CL → little E₂ / lot Progesterone
- 14 days (fixed Duration)
- Endometrium → Secretory



* MID-CYCLE PEAK

- FSH, LH, Estrogen

* Estrogen - 2 peaks

* Progesterone peak

Luteal phase

* Ant. Pit. hormones

Ovarian Changes

Ovarian hormones

Uterine Changes



Homework



- ✓ Read NCERT Complete
- ✓ Extra Questions Solve

———— **FOR NOTES & DPP CHECK DESCRIPTION** ————

THANK YOU

